







A Case Report of Latissimus Dorsi Flap for Skin Coverage after Craniectomy and Duraplasty for Skin Coverage after Widespread Squamous Cell Carcinoma

William Garrett Baker^{1*} , Abhira Raveendran¹ , Gregory Crisafulli¹, Maria-Simona Carnovale¹ , Joanna Sajdlowska¹ , Silvio Podda²

¹General Surgery Department, St. Joseph University Medical Center, Paterson, NJ 07503, USA

²Plastic and Reconstructive Surgery Department, St. Joseph University Medical Center, Paterson, NJ 07503, USA

*Correspondence author: William Garrett Baker, MD, General Surgery Department, St. Joseph University Medical Center, 703 Main St, Paterson, NJ 07503, USA; Email: gbakersjb@gmail.com

Citation: Baker WG, et al. A Case Report of Latissimus Dorsi Flap for Skin Coverage after Craniectomy and Duraplasty for Skin Coverage after Widespread Squamous Cell Carcinoma. *J Surg Res Prac.* 2026;7(2):1-6.

<https://doi.org/10.46889/JSRP.2026.7204>

Received Date: 21-04-2026

Accepted Date: 11-05-2026

Published Date: 19-05-2026



Copyright: © 2026 The Authors. Published by Athenaeum Scientific Publishers.

This is an open access article distributed under the terms of the Creative Commons Attribution 4.0 International License (CC BY 4.0), which permits unrestricted use, distribution and reproduction in any medium, provided the original work is properly cited.

License URL:

<https://creativecommons.org/licenses/by/4.0/>

Abstract

Purpose: The latissimus Dorsi Myocutaneous Flap (LDMF) has a long-standing history in reconstructive surgery and was first introduced by Tansini in the late 19th century. Over time, it has evolved into a reliable option for coverage of large and complex soft tissue defects. The flap offers a robust vascular supply, significant volume and pliability, making it ideal for scalp and calvarial reconstruction, particularly in the irradiated or previously operated fields. We present a case of LDMF used for cranial defect coverage following wide excision of an invasive Squamous Cell Carcinoma (SCC) involving the scalp, calvarium and dura.

Methodology: We describe the surgical technique, rationale for flap selection and postoperative course of a 70-year-old male patient with SCC of the scalp and face requiring extensive resection. Multidisciplinary surgery included wide local excision, craniectomy, duraplasty with collagen matrix and titanium mesh cranioplasty. Given the large scalp and cranial defect, free flap reconstruction was performed using a latissimus dorsi flap. Microvascular anastomosis of the superficial temporal vessels was successfully performed. The postoperative recovery was uneventful and the patient received adjuvant radiotherapy during rehabilitation.

Key findings: Scalp reconstruction after extensive oncologic resection presents unique challenges, particularly when involving the bone and dura. The latissimus dorsi flap provides the necessary tissue bulk, vascularity and surface area for such complex defects. Compared to other options such as the Anterolateral Thigh (ALT) or omental flaps, LDMF offers a longer pedicle length and reliable perfusion. Skin grafting alone is contraindicated because of the exposed hardware and dura.

Principal conclusions: This case highlights the efficacy of a latissimus dorsi free flap in reconstructing large, composite scalp defects involving the bone and dura following oncologic resection. Its reliable anatomy, robust blood supply and ability to conform

to complex defects make it an essential tool for the armamentarium of reconstructive surgeons.

Keywords: Latissimus Dorsi Flap; Scalp Reconstruction; Oncologic Resection; Case Report

Introduction

Scalp reconstruction after oncologic resection remains a complex challenge because of the frequent need for wide composite excisions involving the skin, valvarium and dura. Small or superficial defects can often be managed with primary closure, skin grafting or local tissue rearrangement. However, large, deep or previously irradiated defects with exposed hardware and dura

typically require vascularized free tissue transfer to restore durable coverage and protect critical structures [1-3]. The Latissimus Dorsi Myocutaneous Flap (LDMF) has become a reliable option in these situations due to its large surface area, long pedicle length, robust vascularity and versatility in providing both bulk and pliability [1,4,5]. Indications for its use in scalp reconstruction include extensive oncologic resections, traumatic injuries, burns or reconstruction following failed local flaps and cranioplasty [2,3,6,7].

Despite the availability of alternative flaps such as the Anterolateral Thigh (ALT) and omental flaps, the LDMF remains the widely adopted “workhorse flap” in contemporary reconstructive algorithms [1,6].

We present a case of an elderly patient with invasive squamous cell carcinoma of the scalp requiring wide local excision, craniectomy with dural repair and titanium mesh cranioplasty, successfully reconstructed using free LDMF (Fig. 1).

Case Presentation

A 70-year-old man with a past medical history of chronic lymphocytic leukemia was treated with single systemic chemotherapy and biopsy-proven squamous cell carcinoma presented at an outside hospital for progressive weakness and enlarging lesions of the vertex of the scalp and face. He had previously received intravenous chemotherapy and was followed up by outpatient plastic surgery, but was lost to follow-up due to insurance limitations. Imaging revealed osseous invasion of the calvarium with concern for dural involvement. On admission, antibiotics were started. A multidisciplinary surgical approach involving plastic surgery and neurosurgery was planned for tumor resection, dural repair and cranial defect reconstruction. Chemotherapy was administered when the patient was an inpatient.

Intraoperatively, the eroded scalp skin was excised via Plastic Surgery. A high-speed burr drill craniotomy was performed around the areas of bony tumor involvement. The tumor was resected from the underlying dura, revealing a partial-thickness dural defect at the center of the craniectomy. A collagen matrix graft was used for the duraplasty (Fig. 1).

The calvarial defect measured 6.5 cm in diameter and was reconstructed with a titanium mesh of 10.9 cm in diameter secured using titanium screws. The resulting soft tissue defect measured approximately 12 cm in diameter and a cranial defect measured 6 x 6 cm. Given the size and location of the defect, a free latissimus dorsi muscle flap was selected to provide durable vascularized coverage.

The flap was harvested through a posterior thoracic incision extending from the inferior angle of the scapula to the midline. The muscle was then elevated in a medial-to-lateral and caudal-to-cranial direction to preserve the thoracodorsal vascular pedicle. The latissimus was meticulously separated from the surrounding structures, including the underlying serratus anterior and overlying trapezius, taking care to preserve the adjacent neurovascular bundles. The thoracodorsal vessels were traced proximally along the inferior border of the serratus anterior, providing a pedicle length of approximately 8 cm, suitable for microvascular transfer.

The superficial temporal artery and vein were identified at the recipient site and prepared under a microscope. The vessels were flushed with heparinized saline and an end-to-end arterial and venous anastomosis was completed using interrupted 9-0 nylon sutures. Following confirmation of adequate perfusion, the flap was inset over the cranial reconstruction and secured to the surrounding soft tissue using interrupted 4-0 chromic sutures. A Jackson-Pratt (JP) drain was placed in the subgaleal plane while a Blake drain was positioned at the donor site; both were secured with 2-0 silk suture. The estimated intraoperative blood loss volume was 300 mL.

The patient tolerated the procedure well and was extubated in the operating room. He was monitored in the Surgical Intensive Care Unit (SICU) and transitioned to the surgical floor on postoperative day one. On postoperative day three, the patient returned to the operating room for resurfacing of the latissimus muscle with a split-thickness skin graft. A graft measuring 13 x 16 cm was harvested from the left lateral thigh and secured to the scalp using interrupted 4-0 chromic sutures (Fig.2).

Both the JP and Blake drains were removed at the end of the procedure. The patient was discharged to a rehabilitation facility on postoperative day four. Surgical pathology identified the lesion as a well-differentiated squamous cell carcinoma and the

clinical stage was determined as T2N₀M₀. The skin margins were positive for solar elastosis with actinic changes and cellular atypia, but with no invasive carcinoma. The patient was seen postoperatively by radiation oncology and underwent radical external beam radiation. Oncology was consulted for possible recommendations regarding systemic therapy and initially recommended systemic cisplatin given positive skin margins, but due to the risk of toxicity, considering the proximity to the brain, single-agent radiation therapy was ultimately indicated at this time. The patient subsequently underwent radical beam external radiation five days a week over an 8-week course. The patient tolerated the sessions well and was seen by the radiation oncology department after the conclusion of his radiation sessions. Unfortunately, the patient was lost to follow-up for all specialties and did not complete the recommended course.

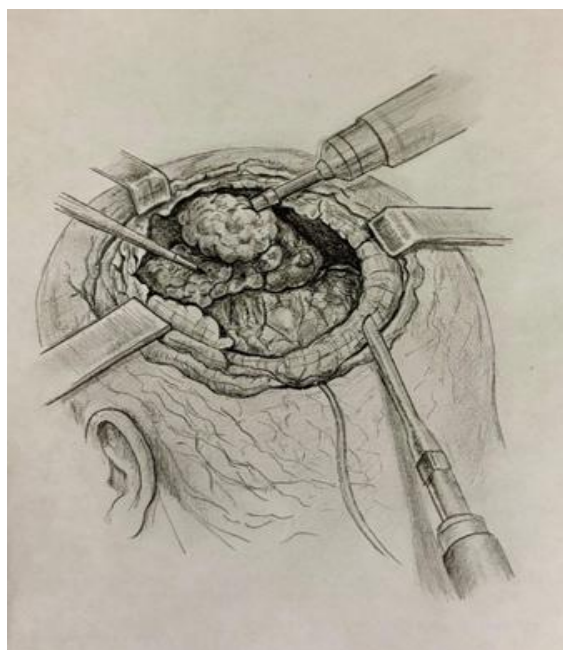


Figure 1: Intraoperative illustration depicting wide local excision of invasive squamous cell carcinoma of the scalp with tumor exposure and retraction.

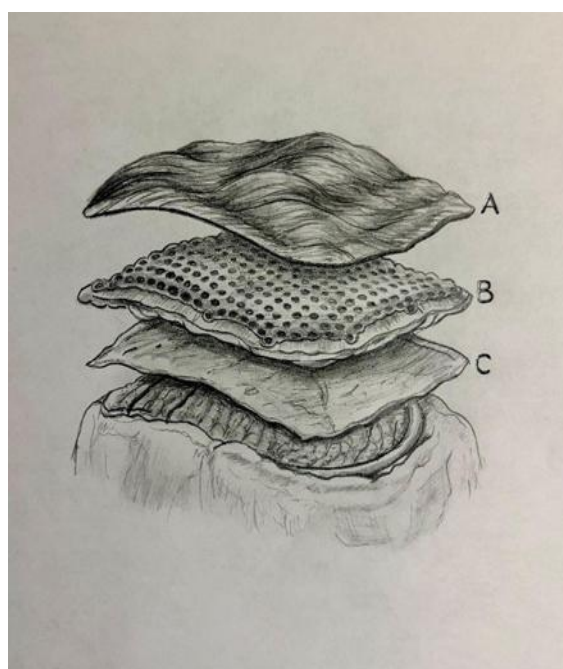


Figure 2: Illustration of the layered cranial reconstruction: (A) latissimus dorsi muscle flap; (B) titanium mesh; (C) collagen matrix.

Discussion

This case highlights the utility of a Latissimus Dorsi Free Flap (LDMF) for complex scalp reconstruction following oncological resection, craniectomy, duraplasty and titanium mesh cranioplasty (Fig. 3). The reconstructive demands in this setting are considerable, requiring well-vascularized soft tissue to protect intracranial contents, provide durable coverage over alloplastic material and tolerate adjuvant therapies such as radiation.

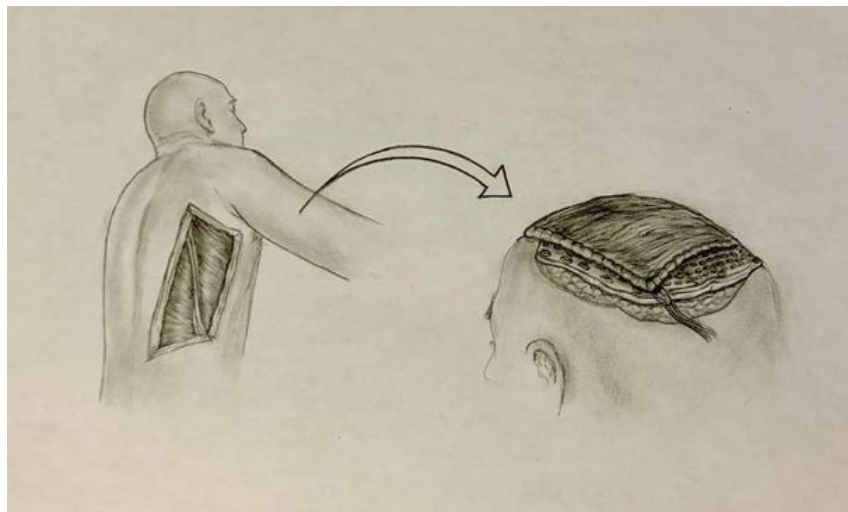


Figure 3: Overview illustration demonstrating harvest of the latissimus dorsi free flap from the posterior thoracic donor site and transfer to the cranial defect for scalp reconstruction.

The LDMF fulfills these requirements because of its consistent vascular anatomy, long pedicle, large surface coverage and pliability, allowing it to conform to irregular cranial contours and establish stable coverage in even the most challenging defects [1,4,5]. Unlike local flaps, which may be insufficient in size or compromised by prior oncologic resections, LDMF offers predictable bulk and reliable perfusion. Comparing it to alternatives such as the Anterolateral Thigh (ALT) flap or omental flap, it provides sufficient volume and pliability without the morbidity of intra-abdominal harvest or the need for frequent secondary thinning procedures [1-3,6,7].

Several case series have reinforced the reliability of this method in high-risk patient populations. Strubing, et al., reported a 12-year experience with scalp reconstruction in which LDMF achieved consistently high success rates, with acute tobacco use identified as a major predictor of flap loss [1]. A retrospective cohort analysis investigating pedicled latissimus dorsi flap reconstruction showed that smoking history was associated with significant risk factors ($P=0.034$). However, with the latissimus dorsi flap, the average survival rate for one year was 84% and 80% at 2 years, with only 12% experiencing major complications. This confirms a higher survival rate, lower rate of severe complications and improved quality of life despite being a significant risk factor [8]. Hierner, et al., emphasized its particular value in subtotal and total scalp defects with exposed dura, where the presence of titanium mesh and dural substitutes precluded skin grafting alone and mandated vascularized tissue coverage [6].

Importantly, our patient had carried additional risk factors, including hematological malignancy and the need for adjuvant radiation therapy. Both conditions are known to impair wound healing and increase the risk of postoperative infection, dehiscence and most importantly, flap compromise. The robust vascularity of LDMF is advantageous in this context as it enhances tissue oxygenation and resistance to infection, thereby improving tolerance to subsequent radiotherapy. Previous studies have shown that free flaps with reliable perfusion allow safer delivery of postoperative radiation, decreasing complications compared to skin grafts or thin local flaps in irradiated fields [2,3]. Strubing, et al., provided statistical evidence in a 12-year retrospective study that demonstrated high reliability in patients who underwent postoperative radiotherapy. Among the 43 patients that were studied, only 2% experienced total flap loss and 26% experienced major complications, with a success rate of 97.7% [9]. Comparing studies on flap-based breast reconstruction, abdominal flaps showed wound dehiscence in a higher proportion of patients ($P=0.045$) compared to those in LDF, further supporting higher success rates with LDF, even with radiotherapy [10].

The staged strategy employed an initial flap inset to achieve vascularized coverage, followed by delayed split-thickness skin grafting, which allowed for the secure protection of intracranial structures while optimizing long-term epithelialization. This aligns with contemporary reconstructive principles for composite scalp defects in oncological patients, balancing oncologic safety, coverage durability and readiness for adjuvant therapy.

Unfortunately, the patient was lost to follow-up after the final outpatient radiation appointment. With the patient's history of CLL and ultimately life-threatening open lesion of invasive SCC, the decision was made after discussion with the inpatient oncology department to hold his ibrutinib. Despite aggressive resection, the patient underwent resection with Plastic Surgery and Neurosurgery with positive pathological margins. Oncology recommended cisplatin systemic therapy, but a recent MRI five months postoperatively identified metastatic disease extending from the right parietal calvarium near the vertex into the extra-axial space and the underlying right parietal lobe. Due to the high likelihood of toxicity, considering the proximity to the brain on the MRI, single-agent radiation at this time was recommended, with plans to address systemic therapy in the future and follow up with his primary oncologist in his hometown. Radiation Oncology recommends radical external beam radiation five days a week over an 8-week course, which the patient received. Unfortunately, during his last radiation treatment, the patient was lost to follow-up for further surveillance.

Overall, this case reinforces the role of LDMF as a versatile and dependable option for scalp reconstruction in high-risk oncological settings. Its consistent anatomy, robust vascular supply and adaptability showcase its continued designation as a "workhorse flap" for large or composite scalp defects, particularly in patients requiring cranioplasty and postoperative radiation [1-7].

Conclusion

The Latissimus dorsi free flap is a reliable and versatile option for the reconstruction of complex scalp defects following oncologic resection, craniectomy, duraplasty and titanium mesh placement. Its consistent vascular anatomy, long pedicle, large surface area and pliability provide durable coverage over the exposed dura and hardware while tolerating adjacent radiotherapy. This case reinforces the role of LDMF as a cornerstone flap for extensive or high-risk scalp defects, particularly in patients with compromised or previously operated wound beds.

Conflict of Interest

The authors declared no potential conflicts of interest with respect to the research, authorship and/or publication of this article.

Funding Statement

This research did not receive any specific grant from funding agencies in the public, commercial or non-profit sectors.

Acknowledgement

Our sincere thanks to the Department of General Surgery in our hospital, the staff working in our operating theatre and the management of the hospital.

Data Availability Statement

The data supporting the findings of this study are available from the corresponding author upon reasonable request.

Ethical Statement

The project did not meet the definition of human subject research under the purview of the IRB according to federal regulations and therefore was exempt.

Informed Consent Statement

Informed consent was obtained from all participants included in the study.

Authors' Contributions

All the authors contributed to the conception and design of the study. The authors performed a literature search and first draft

and the first author drafted and critically revised the work. All authors commented on the previous versions of the manuscript and all authors have read and approved the final manuscript. William Garrett Baker, M.D; Abhira Raveendran, MBDC, B.S; Gregory Crisafulli, M.D, M.S; Maria-Simona Carnovale B.S; Joanna Sajdlowska, D.O, M.S; Silvio Podda M.D

References

1. Strübing F, Thomas B, Wenz F, Etminan N, Bigdeli AK, Vollbach F, et al. Scalp reconstruction using the latissimus dorsi free flap: A 12-year experience. *J Clin Med*. 2023;12(1):1-13.
2. Jang HU, Choi YW. Scalp reconstruction: A 10-year experience. *Arch Craniofac Surg*. 2020;21:237-43.
3. Schwarz F, Dünisch P, Walter J, Sakr Y, Kalff R, Ewald C. Cranioplasty after decompressive craniectomy: Is there a rationale for an initial artificial bone-substitute implant? A single-center experience after 631 procedures. *J Neurosurg*. 2016;124:710-15.
4. Kruse-Losler B, Presser D, Meyer U, Schul C, Luger T, Joos U. Reconstruction of large defects on the scalp and forehead as an interdisciplinary challenge: Experience in the management of 39 cases. *Eur J Surg Oncol*. 2006;32(9):1006-14.
5. Romansky R. Latissimus dorsi (thoracodorsal) flap: The universal reconstructive tool. Sofia (Bulgaria). 2022.
6. Hierner R, van Loon J, Goffin J, van Calenbergh F. Free latissimus dorsi flap transfer for subtotal scalp and cranium defect reconstruction: report of 7 cases. *Microsurgery*. 2007;27(5):425-28.
7. Han Y, Chen Y, Han Y, Chen Z, Li L, Pu W, et al. The use of free myocutaneous flap and implant reinsertion for staged cranial reconstruction in patients with titanium mesh exposure and large skull defects with soft tissue infection after cranioplasty: Report of 19 cases. *Microsurgery*. 2021;41:637-44.
8. Stepniewski A, Krahlisch J, Emmert A, Jebran AF, Schilderth M, Synn H, et al. Latissimus dorsi flap in the treatment of thoracic wall defects after medial sternotomy. *Eplasty*. 2020;20:e4.
9. Strübing F, Wenz F, Etminan N, Bigdeli AK, Siegwart LC, Thomas B, et al. Scalp reconstruction using the latissimus dorsi free flap: A 12-year experience. *J Clin Med*. 2023;12(8):2953.
10. Patel AA, Arquette CP, Rowley MA, Borrelli MR, Lee GK, Nazerali RS. Comparing outcomes of flap-based salvage reconstructions in the radiated breast. *Ann Plast Surg*. 2021;86(5 Suppl 3):S403-8.

About the journal



Journal of Surgery Research and Practice is a peer-reviewed, open-access scholarly journal published by Athenaeum Scientific Publishers. The journal publishes original research articles, case reports, reviews, editorials and commentaries within its defined scope, with the aim of supporting scientific research and clinical knowledge in medical surgery.

All manuscripts are evaluated through an independent peer-review process conducted in accordance with the journal's editorial policies and established publication ethics. Editorial decisions are made solely on the basis of academic merit.

Manuscript submission: <https://athenaeumpub.com/submit-manuscript/>