



# Clinical Outcomes of the Star-Like Technique Described by Ferraro et al. for Correction of Tuberous Breast Deformity: A Large Case Series

Michele Manfrellotti<sup>1\*</sup>, Andrea Giuseppe Ferraro<sup>2\*</sup>, Salvatore Todde<sup>3</sup>, Giuseppe Andrea Ferraro<sup>3</sup>

<sup>1</sup>Università degli studi di Salerno, Italy

<sup>2</sup>Università degli studi di Napoli Federico II, Italy

<sup>3</sup>Università degli studi del Molise, Italy

\*Correspondence author: Michele Manfrellotti, Università degli studi di Salerno, Italy and Andrea Giuseppe Ferraro, Università degli studi di Napoli Federico II, Italy; Email: [michele.manfrellotti98@gmail.com](mailto:michele.manfrellotti98@gmail.com); [agferraro99@libero.it](mailto:agferraro99@libero.it)

Citation: Manfrellotti M, et al. Clinical Outcomes of the Star-Like Technique Described by Ferraro et al. for Correction of Tuberous Breast Deformity: A Large Case Series. *J Surg Res Prac*. 2026;7(2):1-9.

<https://doi.org/10.46889/JSRP.2026.7206>

Received Date: 10-05-2026

Accepted Date: 27-05-2026

Published Date: 04-06-2026



Copyright: © 2026 The Authors. Published by Athenaeum Scientific Publishers.

This is an open access article distributed under the terms of the Creative Commons Attribution 4.0 International License (CC BY 4.0), which permits unrestricted use, distribution and reproduction in any medium, provided the original work is properly cited.

License URL:

<https://creativecommons.org/licenses/by/4.0/>

## Abstract

**Background:** Tuberous breast deformity is a complex congenital condition characterized by breast base constriction, glandular hypoplasia and nipple-areola complex distortion. Although multiple surgical techniques have been described, the management of moderate to severe forms remains challenging, particularly with regard to reproducibility and long-term stability of outcomes. The present study evaluates a large clinical series treated with the star-like incision technique described by Ferraro, et al., focusing on indications, clinical outcomes and safety.

**Methods:** Between 2009 and 2025, 230 patients diagnosed with tuberous breast deformity underwent surgical correction using a single-stage star-like glandular incision combined with subfascial placement of round high profile silicone breast implants. Deformities were classified according to the Grolleau system. All procedures were performed by the same surgical team. Postoperative assessment included scheduled clinical follow-up, standardized photographic documentation and a patient satisfaction questionnaire.

**Results:** Correction of breast base constriction and NAC herniation was achieved in nearly all patients, with consistent improvement in breast contour, lower pole expansion and overall symmetry. Early complications included superficial wound dehiscence in 15 patients (6.5%), managed conservatively. No infections or revision surgeries were recorded. The mean follow-up duration was 36 months (range 12-60 months). During the available follow-up period, no clinically relevant capsular contracture was observed. Patient-reported outcomes indicated a high overall level of satisfaction.

**Conclusion:** In this clinical series, the star-like incision technique according to Ferraro, et al., appears to represent a reproducible option for the correction of selected moderate to severe forms of tuberous breast deformity. The retrospective design and

absence of a control group represent limitations of the study; further comparative investigations are required to better define the role of this technique among available surgical strategies.

**Level of Evidence:** IV, therapeutic study based on a retrospective case series.

**Keywords** Tuberous Breast Deformity; Grolleau System; Surgical Strategies

## Introduction

Tuberous breast deformity is a congenital anomaly characterized by variable degrees of breast base constriction, glandular hypoplasia, skin deficiency particularly of the lower pole and herniation of the Nipple-Areola Complex (NAC) [1-13]. Since its first description by Rees and Aston, this condition has remained a challenging entity in plastic and reconstructive breast surgery due to its heterogeneous presentation and the absence of a universally accepted classification or treatment algorithm [2,3,14-17]. The deformity typically becomes evident during puberty, when normal breast development is disrupted by abnormal structural constraints that limit radial glandular expansion [9-11]. As a consequence, the breast may assume a tubular configuration with associated asymmetry, areolar enlargement, malposition of the Inframammary Fold (IMF) and disproportionate projection of the NAC [8,12]. The clinical spectrum ranges from mild forms with isolated areolar herniation to severe deformities involving all breast quadrants [13]. Several classification systems have been proposed to facilitate diagnosis and surgical planning. Among these, the systems described by von Heimburg, et al., Grolleau, et al., and later refinements including the addition of a "Type 0" deformity, have contributed to a more structured understanding of the condition [3,8,15]. Nevertheless, classification alone has not translated into standardized management, as surgical correction often requires an individualized combination of glandular remodeling, release of constricting elements, correction of areolar abnormalities and volume restoration [10,16]. Over the years, numerous surgical techniques have been described, including local dermoglandular flaps, tissue expansion with staged reconstruction, dual-plane or submuscular implant placement and adjunctive lipofilling [13,18-22]. While these approaches may be effective in selected cases, moderate to severe deformities continue to pose difficulties in achieving predictable breast shape, adequate lower pole expansion and long-term stability without excessive surgical complexity or staged procedures [10,17]. The star-like glandular incision technique described by Ferraro, et al., was developed to address these challenges by allowing controlled internal redistribution of glandular tissue through a geometric pattern of deep, star-shaped, parenchymal incisions, combined with high profile implant-based volume support [1]. The technical principles of this approach have already been detailed in the original publication and will not be reiterated extensively in the present study. The aim of this manuscript is not to introduce a new surgical technique, but rather to evaluate the clinical application of the star-like incision approach in a large consecutive series of patients. Specifically, this study analyzes indications, outcomes, complication profile and long-term clinical behavior of the technique when applied to a broad spectrum of tuberous breast deformities.

## Indications

The star-like glandular incision technique is indicated for selected patients presenting with tuberous breast deformity characterized by moderate to severe structural constriction of the mammary base and associated glandular hypoplasia [1,15]. Its application should be guided by careful clinical assessment and classification of the deformity rather than by a uniform indication. In the present series, patient selection was primarily based on the classification proposed by Grolleau, et al. [15]. The technique was preferentially applied in patients with Type II and Type III deformities, in whom hypoplasia of the lower pole and circumferential base constriction represent the dominant anatomical features [13,16]. In these cases, isolated implant augmentation is often insufficient to correct the underlying deformity and internal glandular release is required [10,18]. Patients with Type I deformity were considered on an individual basis, while those with Type 0 deformity characterized by isolated areolar herniation and a normal breast base were generally managed using less invasive corrective procedures [3]. Most patients underwent primary correction, while a limited number of cases represented secondary procedures performed for persistent base constriction or recurrent areolar herniation [17]. Cases with extensive scarring, compromised tissue quality or minimal residual glandular tissue were approached with caution. All procedures were combined with implant placement to address volume deficiency and provide support to the remodeled gland. Subfascial high profile implant placement was used in this series; however, this approach may be less suitable in patients with very thin soft-tissue envelopes, emphasizing the importance of individualized surgical planning [1,22].

## Materials and Methods


**Study Design and Patient Population:** This retrospective observational study included 230 consecutive female patients treated for tuberous breast deformity between 2009 and 2025. All patients underwent surgical correction using the same operative approach, performed by the same surgical team. Preoperative evaluation included medical history, physical examination, standardized photographic documentation and breast imaging when indicated to exclude underlying pathology. Deformities were classified according to the Grolleau system [15].

### *Preoperative Markings*

Preoperative markings were performed with the patient in standing and supine positions, following standard aesthetic breast surgery principles [6,10]. A midline reference and breast meridian were drawn and the new NAC position was marked along the jugular-nipple axis. In advanced deformities, the areolar diameter was defined using a 40 mm areolotome. The IMF was redrawn when absent or malpositioned. Surgical Technique: After infiltration with diluted epinephrine solution (1:100,000), access was obtained through a periareolar incision, as previously described [1,6]. Partial inferior periareolar incisions were used in Grolleau type I-II deformities, while complete periareolar incisions were used in type III cases. Dissection was carried out between the gland and the pectoralis major fascia, allowing full mobilization of the lower pole [1]. No dissection was performed between the skin and the gland. Controlled full-thickness parenchymal incisions were made to release constricting elements. A five-pointed star-shaped incision was created on the posterior surface of the gland, as originally described by Ferraro, et al. [1]. The resulting glandular flaps were temporarily stabilized in “open” position with interrupted 3-0 Vicryl sutures to maintain expansion during implant placement.

### *Implant Placement and Closure*

Round silicone high profile gel implants were placed in a subfascial pocket [1,22]. The subfascial pocket does not interfere with glandular expansion, as the star-like incisions are performed within the parenchyma and the fascia remains intact over the pectoralis major. Implant size and profile were selected based on anatomical measurements and desired volume. In cases of absent or poorly defined IMF, implant positioning contributed to fold definition. Layered closure was performed with absorbable sutures for deep tissues and a continuous intradermal periareolar suture [6]. Suction drains were placed for 48 hours (Fig. 1).



**Figure 1:** Implant placement.

### *Postoperative Care and Follow-up*

Patients were followed clinically at regular intervals during the first postoperative year and annually thereafter. Outcome assessment included clinical examination, photographic documentation and a patient-reported satisfaction questionnaire.

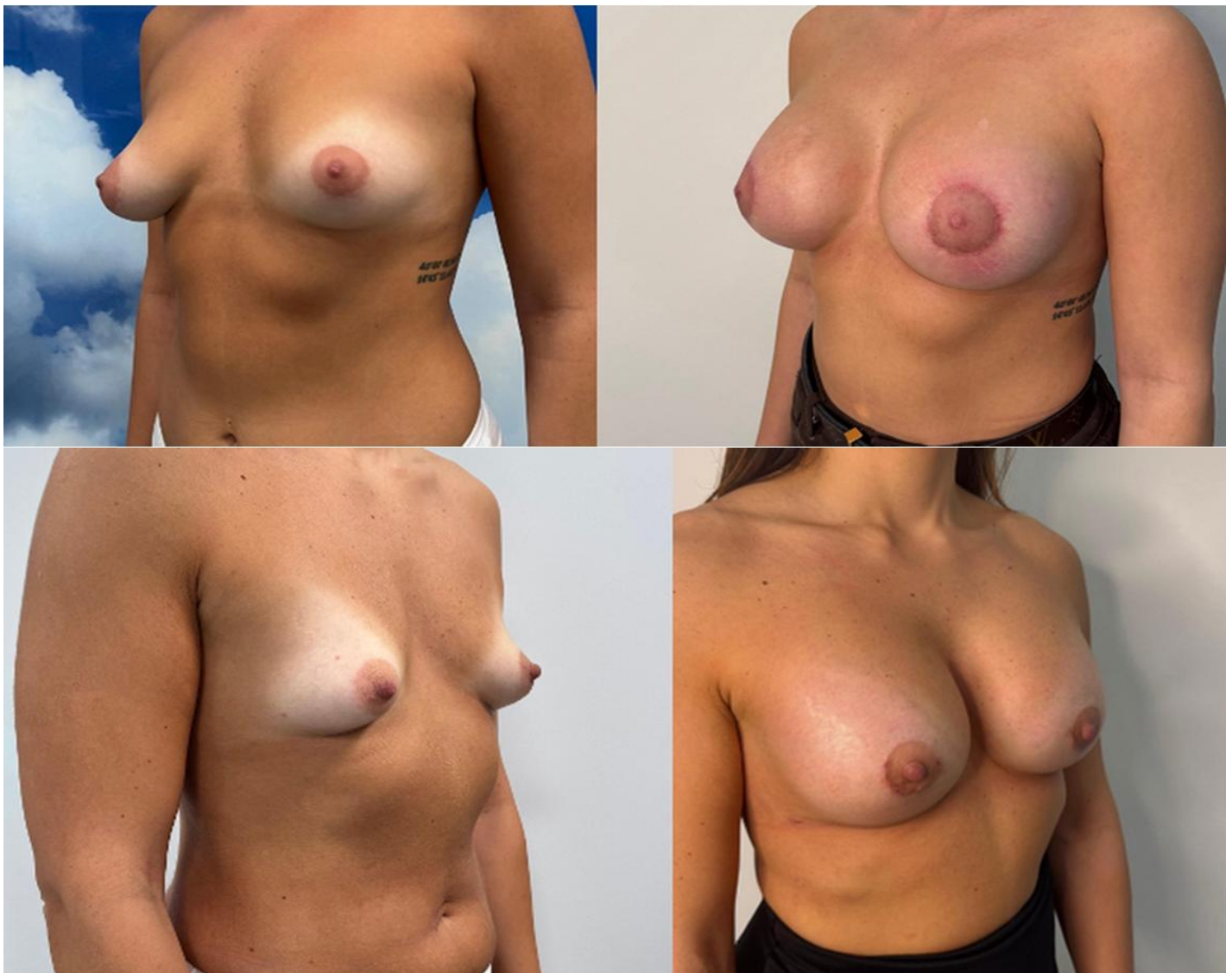## Results

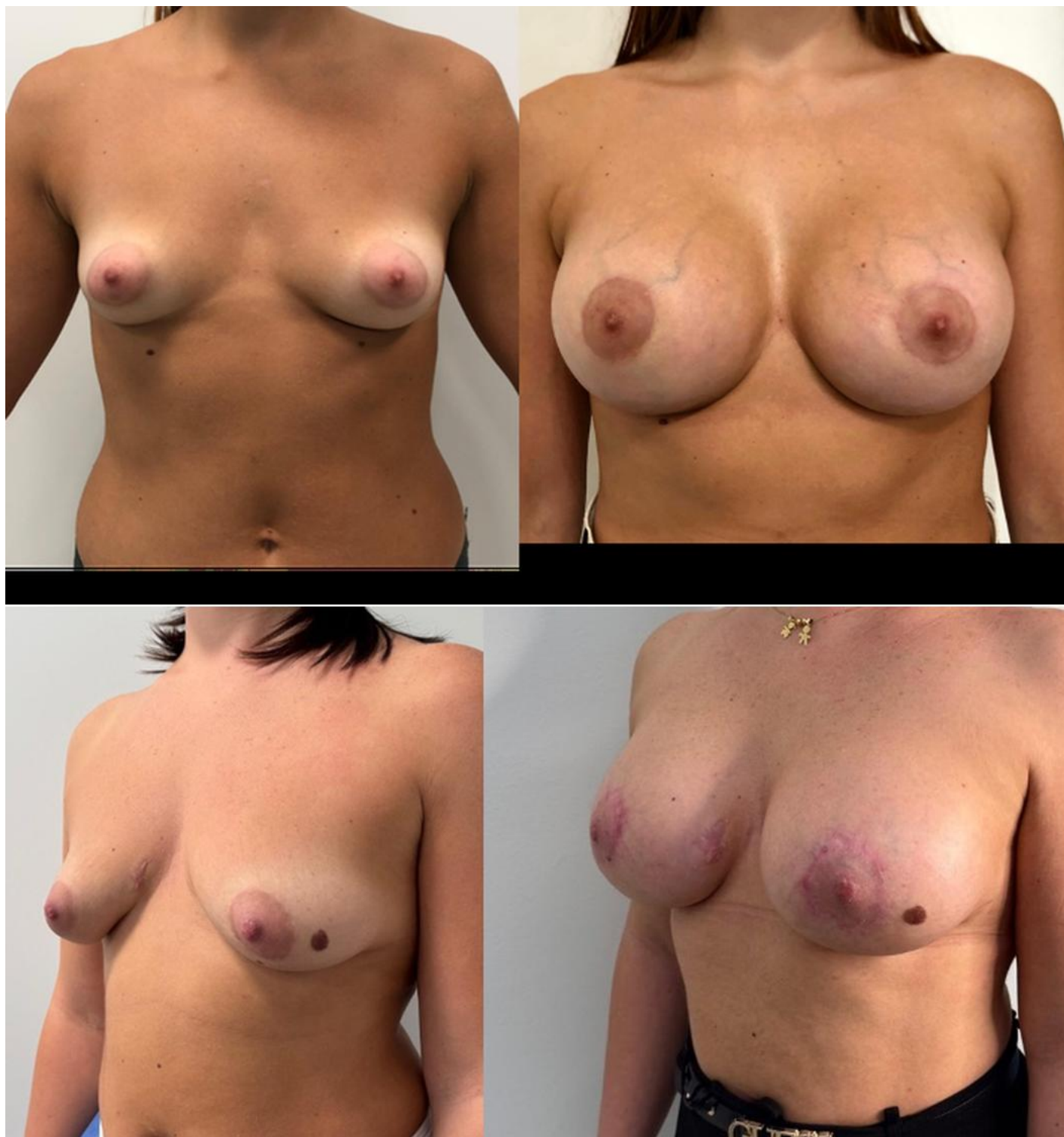**Patient Characteristics and Follow-up:** The mean patient age was  $30 \pm 10$  years. 38% exhibited preoperative asymmetry. Most patients underwent primary correction, while a limited number of cases represented secondary procedures performed for persistent base constriction or recurrent areolar herniation. The mean follow-up duration was 36 months (range 12-60 months). All 230 patients had a minimum follow-up of 12 months.

**Surgical Outcomes:** Correction of breast base constriction and NAC herniation was achieved in nearly all patients, with consistent improvement in breast contour, lower pole expansion and overall symmetry [1]. In 88 asymmetric cases, high profile implants ranging from 250 to 405 cc were used to achieve volume balance.

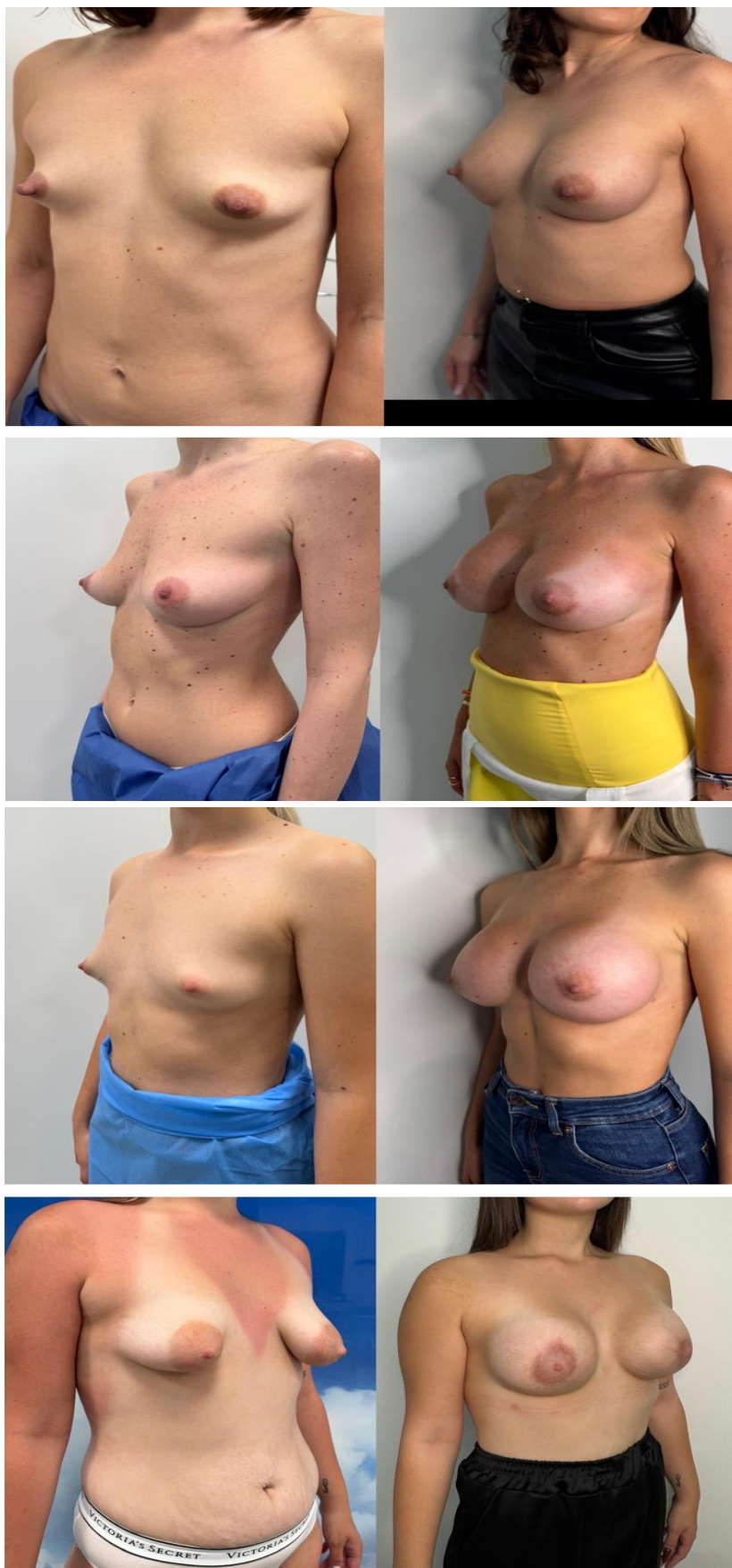**Complications:** Early complications were limited to superficial wound dehiscence in 15 patients, managed conservatively. Minor ecchymosis resolved spontaneously. No infections or revision surgeries were recorded. Capsular contracture was assessed clinically according to the Baker classification. No clinically relevant capsular contracture was observed during follow-up, although this finding should be interpreted in light of the retrospective design [17].

**Patient-Reported Outcomes:** Patient satisfaction was high, with 90 patients reporting satisfaction and 140 reporting high satisfaction. Items related to recurrence did not reveal clinically significant concerns during follow-up (Fig. 2,3).





**Figure 2:** Pre and postoperative (a, b, c, d) views of 4 different patients with bilateral tuberous breast deformity. Postoperative photographs were obtained 1 month after single-stage correction using the star-like glandular incision technique combined with subfascial high profile implant placement. Representative early postoperative images are shown for illustrative purposes; long-term stability was confirmed during follow-up.



**Figure 3:** Pre and postoperative (e, f, g, h) views of 4 different patients with bilateral tuberous breast deformity. Postoperative photographs were obtained 1 year after single-stage correction using the star-like glandular incision technique combined with subs fascial high profile implant placement.

## Discussion

**Structural Basis of the Deformity:** the correction of tuberous breast deformity requires structural remodeling rather than simple volumetric augmentation [10,13]. The present study reports a large clinical experience with the star-like glandular incision technique, focusing on clinical outcomes and limitations rather than on technical novelty. Tuberous breast deformity is primarily characterized by intrinsic glandular constriction and abnormal distribution of parenchymal tissue. Consequently, successful correction requires release of the constricting elements and redistribution of glandular tissue rather than simple implant-based augmentation.

### *Comparison with Classical Glandular Remodeling Techniques*

The technique described by Ribeiro, et al., represents a fundamental contribution to the surgical management of tuberous breast deformity and remains a valuable option, particularly for lower pole expansion through dermoglandular flap transposition [18]. The star-like glandular incision technique is based on a different biomechanical principle, relying on controlled internal parenchymal release rather than tissue transposition. This approach enables multidirectional expansion of the constricted breast base while preserving tissue continuity. In moderate to severe deformities, particularly Grolleau types II and III, the star-like technique allows simultaneous correction of base constriction, areolar herniation and volume deficiency in a single-stage procedure. These conceptual differences may represent an advantage in selected anatomical patterns, although they should not be interpreted as evidence of overall superiority. The choice of technique should remain individualized and comparative studies are required to define their respective roles more precisely. **Role of Lipofilling-Based Strategies:** lipofilling-based strategies, as described by Abboud, et al., represent a valuable option for mild tuberous breast deformities, particularly in patients desiring implant-free correction [19]. However, in moderate to severe cases, fat grafting alone may be insufficient to address structural base constriction and often requires staged procedures. In these situations, the star-like incision technique provides immediate glandular remodeling and predictable shape correction in a single-stage approach.

### *Implant-Based Approaches*

Panchapakesan and Brown described an implant-based strategy for the correction of tuberous breast deformity using anatomical cohesive silicone gel implants combined with selective glandular scoring and lower pole expansion [20]. Their approach focuses primarily on restoring breast volume and projection through implant placement, while limited parenchymal release is used to improve lower pole contour. This strategy may be effective in patients with mild to moderate deformities, where glandular maldistribution and base constriction are less pronounced. However, in more advanced deformities characterized by circumferential base constriction and significant parenchymal distortion, implant placement alone, even when combined with limited scoring, may not provide sufficient lower pole expansion. In such cases, inadequate release of the constricting elements may contribute to contour irregularities, double-bubble deformity or secondary implant malposition. In contrast, the star-like glandular incision technique directly addresses the structural components of the deformity through multidirectional internal parenchymal release, allowing controlled redistribution of glandular tissue and more uniform expansion of the constricted base. When combined with implant-based volume restoration, this approach facilitates simultaneous correction of glandular architecture and breast projection.

### *Multimodal Strategies*

Chan, et al., described a multimodal approach combining subglandular implants with adjunctive procedures such as parenchymal scoring, glanduloplasty and areolar reduction [21]. Their strategy aims to improve projection and symmetry through implant-based reshaping while selectively modifying glandular architecture. In contrast, the star-like glandular incision technique relies primarily on structured radial division of the lower pole parenchyma. The conceptual difference lies not in the use of implants, but in the degree of intrinsic glandular reorganization. While implant-based approaches primarily modify breast projection and surface contour, the star-like configuration directly addresses the constricting ring and base deficiency through controlled sectorial expansion of glandular tissue.

### *Comparison with the Puckett Technique*

Puckett and Concannon described the so-called unfurling technique for the treatment of the narrow-based breast and the prevention of the double-bubble deformity following augmentation mammoplasty [12]. Their approach is performed through a periareolar incision and involves the creation of a plane between the breast parenchyma and the overlying skin, extending inferiorly to the level of the pectoral fascia. The posterior attachment of the lower breast tissue is then incised, allowing the

inferior pole of the gland to “unfurl” and advance downward over the implant pocket. This maneuver effectively increases the available surface of the lower pole and reduces the risk of contour deformities caused by base constriction. Although both the unfurling technique and the star-like glandular incision aim to address intrinsic lower pole deficiency, the mechanisms through which expansion is achieved differ substantially. In the unfurling technique, expansion results primarily from mobilization and inferior advancement of the breast parenchyma after release of its posterior attachments. The correction is therefore obtained by allowing the glandular envelope to reposition over the implant pocket. In contrast, the star-like glandular incision technique is based on a structured intraparenchymal remodeling of the lower pole. Through radial sectorial divisions of the glandular tissue, the constricting ring is released and the parenchyma can be redistributed in multiple directions. This configuration allows controlled expansion of the breast base and facilitates a more homogeneous redistribution of glandular tissue prior to implant placement. From a conceptual standpoint, the unfurling technique primarily relies on tissue mobilization, whereas the star-like approach introduces a geometric reorganization of the glandular architecture. Both strategies therefore address the structural component of tuberous breast deformity, but through different biomechanical principles. The choice between these approaches should be guided by the severity of the deformity, the degree of base constriction and the characteristics of the glandular envelope.

#### *Comparative Advantages of the Star-Like Technique*

The principal advantage of the star-like glandular incision technique lies in its structured approach to intrinsic lower pole constriction. Unlike implant-centered strategies that primarily improve projection and surface contour, the star-like configuration directly addresses the parenchymal constricting ring through radial sectorial division. This allows controlled expansion of the breast base prior to implant placement. Compared with glandular scoring techniques, which increase tissue compliance through multiple partial-thickness incisions, the star-like approach provides a greater degree of geometric control. By dividing the lower pole into predefined radial sectors, glandular redistribution can be directed along specific vectors, allowing predictable expansion of the breast base and improved correction of areolar herniation. Another potential advantage is the ability to combine base expansion, correction of areolar protrusion and volume augmentation within a single structured maneuver. This integrated approach may reduce the risk of under-expansion of the lower pole, which can occur when implant-based strategies are used without sufficient intrinsic glandular release.

#### **Limitations**

Despite these advantages, the technique is technically demanding and requires careful preservation of glandular vascularity. In mild deformities, less invasive approaches such as limited glandular scoring or implant-based reshaping may be sufficient and the additional parenchymal division of the star-like method may not be necessary [17].

#### **Conclusion**

Within the limitations of this retrospective case series, the star-like glandular incision technique according to Ferraro, et al., represents a reproducible surgical option for selected moderate to severe forms of tuberous breast deformity. Careful patient selection and individualized planning remain essential. Further comparative studies are required to better define its role relative to other surgical strategies.

#### **Conflict of Interest**

The authors declared no potential conflicts of interest with respect to the research, authorship and/or publication of this article.

#### **Funding Statement**

This research did not receive any specific grant from funding agencies in the public, commercial or non-profit sectors.

#### **Acknowledgement**

The authors have no acknowledgments to declare.

#### **Ethical Statement**

All procedures performed in studies involving human participants were in accordance with the ethical standards of the institutional and/or national research committee and with the 1964 Helsinki declaration and its later amendments or comparable ethical standards.

## Data Availability Statement

The data supporting the findings of this study are available from the corresponding author upon reasonable request.

## Informed Consent Statement

Informed consent was obtained from all participants included in the study.

## Authors' Contributions

All authors contributed equally to this paper.

## References

- Ferraro GA, De Francesco F, Nicoletti GF. Tuberos breast correction by using a single-stage "star-like" incision: An innovative technique. *Eur J Plast Surg.* 2017;40:525-32.
- Rees TD, Aston SJ. The tuberos breast. *Clin Plast Surg.* 1976;3:339-47.
- Costagliola M, Bishara A, Florence R. Tuberos breast: Revised classification and new hypothesis for its development. *Aesthetic Plast Surg.* 2013;37(5):896-903.
- Bostwick J. *Plastic and Reconstructive Breast Surgery.* St. Louis: Quality Medical Publishing. 1990.
- Williams G, Hoffman S. Mammoplasty for tubular breasts. *Aesthetic Plast Surg.* 1981;5:51-6.
- Gruber RP, Jones HW. The "donut" mastopexy: Indications and complications. *Plast Reconstr Surg.* 1980;65:34-8.
- Bass CB. Herniated areolar complex. *Ann Plast Surg.* 1978;1:401-5.
- von Heimburg D, Exner K, Kruff S, Lemperle G. The tuberos breast deformity: Classification and treatment. *Br J Plast Surg.* 1996;49:339-45.
- Nielsen LJ, Jensen LT. Diagnosing and treating tuberos breast deformity. *Ugeskr Laeger.* 2017;179(4):V07160472.
- Mandrekas AD, George J, Zambacos GJ. Aesthetic reconstruction of the tuberos breast deformity: A 10-year experience. *Aesthet Surg J.* 2010;30:680-92.
- Mandrekas AD, Zambacos GJ, Anastasopoulos A, Hapsas D, Lambrinaki N, Ioannidou-Mouzaka L. Aesthetic reconstruction of the tuberos breast deformity. *Plast Reconstr Surg.* 2003;112:1099-108.
- Puckett CL, Concannon MJ. Augmenting the narrow-based breast: The unfurling technique to prevent the double-bubble deformity. *Aesthetic Plast Surg.* 1990;14:15-9.
- Meara JG, Kolker A, Bartlett G, Thiele R, Mutimer K, Holmes AD. Tuberos breast deformity: Principles and practice. *Ann Plast Surg.* 2000;45:607-11.
- Killinger F, Valeriano V, Di Tommaso L. Quantitative analysis of the histological features of tuberos breast. *Aesthetic Plast Surg.* 2022;46(2):605-11.
- Grolleau JL, Lanfrey E, Lavigne B, Chavoïn JP, Costagliola M. Breast base anomalies: Treatment strategy for tuberos breasts, minor deformities and asymmetry. *Plast Reconstr Surg.* 1999;104:2040-8.
- Pacifico MD, Kang NV. The tuberos breast revisited. *J Plast Reconstr Aesthet Surg.* 2007;60:455-64.
- Van Durme J, Cooreman A, Paternoster J, Vranckx JJ. The different surgical strategies for treating tuberos breast deformity: A scoping review. *JPRAS Open.* 2024;42:11.
- Ribeiro L, Canzi W, Buss AJR, Accorsi AJR. Tuberos breast: A new approach. *Plast Reconstr Surg.* 1998;101:42-50.
- Abboud MH, Abboud NM, El Hajj H. A novel approach for tuberos breast correction using power-assisted liposuction, loops and lipofilling (P.A.L.L.L.). *Aesthet Surg J.* 2022;42(5).
- Panchapakesan V, Brown MH. Management of tuberos breast deformity with anatomic cohesive silicone gel breast implants. *Aesthetic Plast Surg.* 2008;33(1):49-53.
- Chan W, Mathur B, Slade-Sharman D. Developmental breast asymmetry. *Breast J.* 2025.

## About the journal



Journal of Surgery Research and Practice is a peer-reviewed, open-access scholarly journal published by Athenaeum Scientific Publishers. The journal publishes original research articles, case reports, reviews, editorials and commentaries within its defined scope, with the aim of supporting scientific research and clinical knowledge in medical surgery.

All manuscripts are evaluated through an independent peer-review process conducted in accordance with the journal's editorial policies and established publication ethics. Editorial decisions are made solely on the basis of academic merit.

**Manuscript submission:** <https://athenaeumpub.com/submit-manuscript/>