


# Multidisciplinary Management of Congenitally Missing Maxillary Lateral Incisor: Digital Planning and Implant-Prosthetic Rehabilitation

Martha Lucia Trivino Tarazon<sup>1</sup>, Sonia Maria Aguilera Acosta<sup>2</sup>, Luisana Rodríguez<sup>3\*</sup> 

<sup>1</sup>Orthodontist - Fundación Universitaria San Martín | Colegio Odontológico Colombiano

<sup>2</sup>Universidad Nacional Autónoma de Nicaragua

<sup>3</sup>Boston University, United States, DDS - Universidad de Carabobo, Venezuela

\*Correspondence author: Luisana Rodríguez, DMD - Boston University, United States, DDS - Universidad de Carabobo, Venezuela;  
E-mail: [lrodriguez29@gmail.com](mailto:lrodriguez29@gmail.com)

Citation: Tarazon MLT, et al. Multidisciplinary Management of Congenitally Missing Maxillary Lateral Incisor: Digital Planning and Implant-Prosthetic Rehabilitation. *J Dental Health Oral Res.* 2026;7(2):1-15.

<https://doi.org/10.46889/JDHOR.2026.7206>

Received Date: 25-04-2026

Accepted Date: 18-05-2026

Published Date: 25-05-2026



Copyright: © 2026 The Authors. Published by Athenaeum Scientific Publishers.

This is an open access article distributed under the terms of the Creative Commons Attribution 4.0 International License (CC BY 4.0), which permits unrestricted use, distribution and reproduction in any medium, provided the original work is properly cited.

License URL:

<https://creativecommons.org/licenses/by/4.0/>

## Abstract

The congenital absence of maxillary lateral incisors represents one of the most frequent dental anomalies encountered in clinical practice, affecting approximately 2% of the population and demanding a carefully coordinated multidisciplinary approach. This case report describes the comprehensive management of an 18-year-old male patient presenting with the clinical and radiographic absence of tooth #12, compounded by generalized dental malposition, reduced mesiodistal space at the agenesis site, residual ridge buccal deformity, short clinical crowns and altered passive eruption (Type I-A). Treatment was executed in sequential phases involving corrective orthodontics, mucogingival crown lengthening surgery, fully digital prosthetic and surgical planning, computer-guided implant placement with simultaneous guided bone regeneration, soft tissue conditioning via a screw-retained PMMA provisional restoration and delivery of the definitive screw-retained ceramic crown. The outcome demonstrated successful osseointegration, harmonious soft tissue architecture and restoration of anterior esthetics and function. This report underscores the critical role of digital workflow integration and interdisciplinary coordination in achieving predictable outcomes in the esthetic zone.

**Keywords:** Dental Agenesis; Maxillary Lateral Incisor; Implant Rehabilitation; Digital Workflow; Guided Bone Regeneration; Multidisciplinary Dentistry

## Introduction

"Tooth agenesis is the most prevalent craniofacial congenital malformation in humans." ("The genetic basis of tooth agenesis: basic concepts and genes involved") excluding third molars, the maxillary lateral incisor is the second most commonly missing permanent tooth, with a reported population prevalence of approximately 2% [1,2]. Its absence generates a cascade of clinical challenges: space loss from mesial drift of adjacent teeth, alveolar ridge atrophy, compromised occlusal function and significant esthetic impairment, particularly relevant in the anterior maxillary zone.

Two primary treatment philosophies have historically dominated management: orthodontic space closure with canine substitution and orthodontic space opening followed by prosthetic replacement, most predictably with a single-tooth' implant-supported crown [3,4]. Each approach carries distinct advantages and disadvantages contingent on the patient's skeletal class, occlusal relationship, ridge morphology, smile line and gingival biotype [3].

Implant-based rehabilitation in the esthetic zone demands meticulous pre-surgical planning to ensure adequate hard and soft

tissue dimensions, correct three-dimensional implant positioning and harmonious peri-implant emergence profile [5,6]. The integration of digital tools, intraoral scanning, Computer-Aided Design and Manufacturing (CAD/CAM) and virtual implant planning, has substantially improved the precision of treatment delivery and reduced operator-dependent variability [5].

This case report documents the multidisciplinary, digitally driven management of a young adult patient with congenitally missing tooth #12, encompassing orthodontic preparation, periodontal surgery, guided implant surgery and prosthetic rehabilitation, with an emphasis on the sequential clinical decision-making process.

## **Case Report: Multidisciplinary Approach and Case Management**

### *Patient Presentation*

An 18-year-old male patient presented to the clinic with the chief complaint of a missing upper lateral tooth and altered smile esthetics. Medical history was non-contributory. Clinical and radiographic examination confirmed the complete absence of tooth #12 [3].

The dental history was notable for fusion of the primary teeth #51 and #52 (fused clinical crowns), which are known to be associated with agenesis of their successors. Upon eruption of the permanent dentition, tooth #12 failed to emerge and no radiographic evidence of a tooth germ was identified. Additional findings included:

- Generalized dental malposition
- Reduced mesiodistal space in the region of tooth #12
- Buccal residual ridge deformity at the agenesis site
- Short clinical crowns throughout the anterior maxilla
- Altered passive eruption, classified as Type I-A per Coslet, et al.,

### *Diagnostic Workup and Initial Planning*

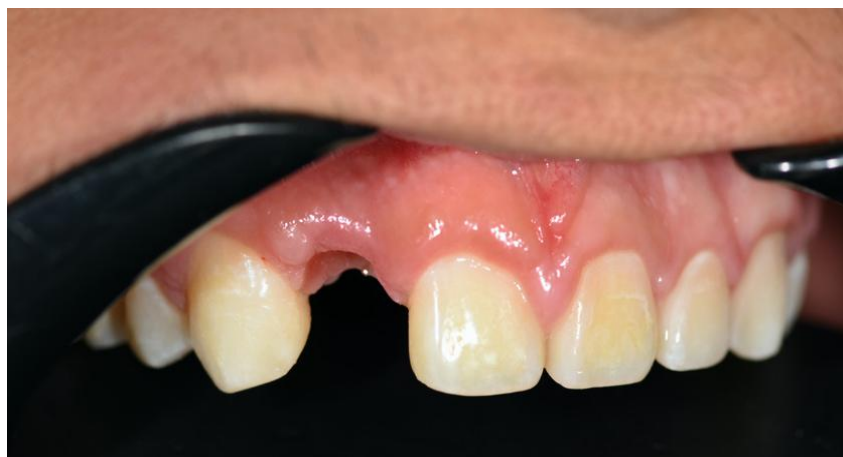A comprehensive evaluation of periodontal, dental and craniomandibular conditions was completed. An intraoral scan was acquired using the OVO Intraoral Optical Scanning (IOS) system. A digital wax-up was developed in Exocad software to define the target occlusal scheme and establish the required mesiodistal prosthetic space in the agenesis zone. Three-dimensional virtual implant positioning was subsequently planned to use BlueSkyPlan4 software overlaid on Cone-Beam Computed Tomography (CBCT) data, confirming adequate bone volume and establishing the precise angulation and depth for the planned BioHorizons TLX3015 implant (3 mm diameter, 15 mm length) at a placement angle of 21.72 degrees. Safety margins of 2.04 mm and 2.24 mm from the adjacent root surfaces were verified in the planning software.

### *Treatment*

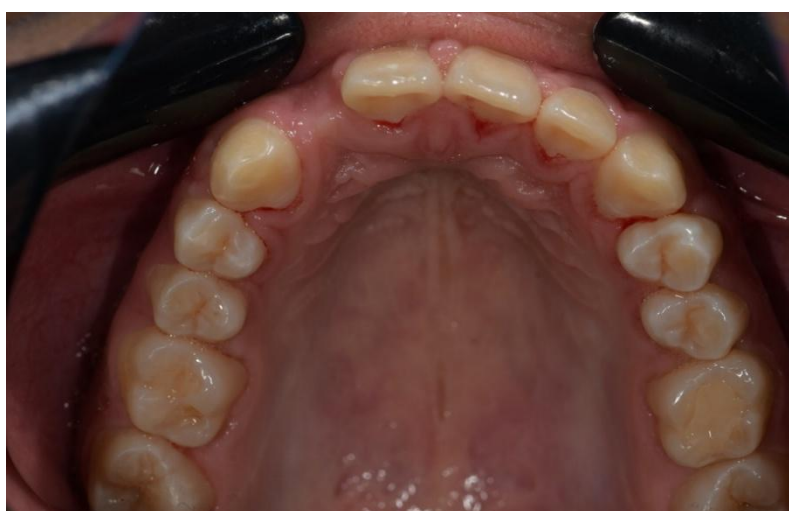#### *Phase 1: Corrective Orthodontics*

Fixed orthodontic therapy was initiated to align and level the dentition, establish appropriate anterior and posterior guidance, achieve bilateral canine disocclusion and recover the mesiodistal prosthetic space required for implant placement in the #12 region [3,4].

This phase was completed over 12 months. Upon bracket removal, clinical examination confirmed adequate space recovery and root parallelism of the teeth adjacent to the implant site (Fig. 1,2).



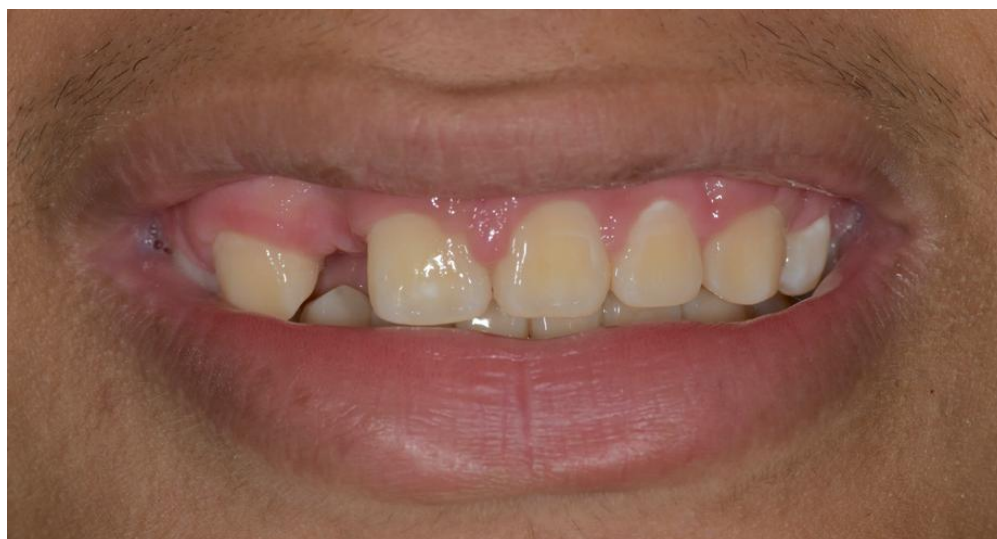**Figure 1:** Lateral View after orthodontic treatment.



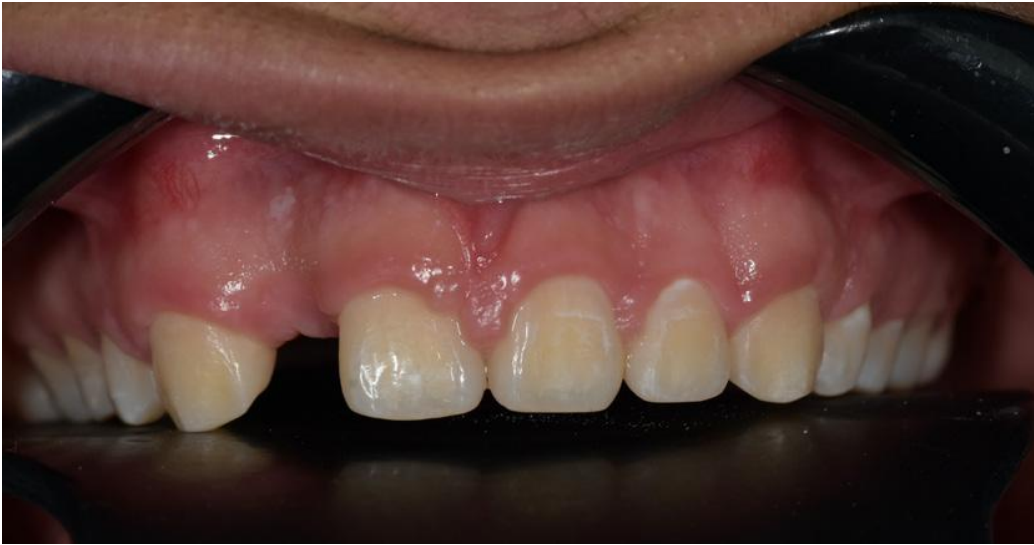**Figure 2:** Occlusal view after orthodontic treatment.

#### *Phase 2: Crown Lengthening Surgery*

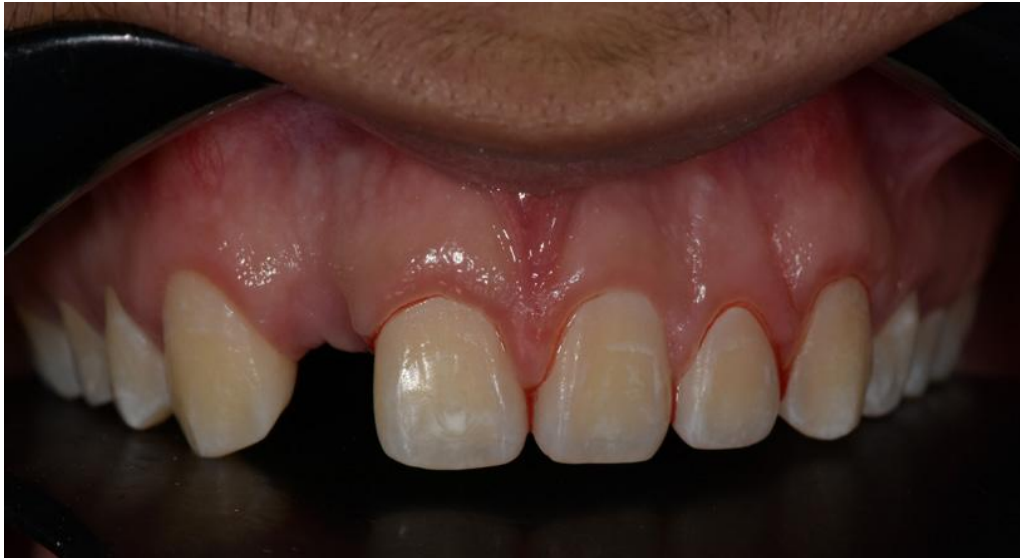Plastic mucogingival surgery was performed to correct the altered passive eruption and increase clinical crown height from tooth #15 to #25. The procedure was carried out using an electroscalpel technique, exposing the appropriate amount of anatomical crown structure and establishing a harmonious gingival architecture prior to prosthetic rehabilitation (Fig. 3-5) [1].



**Figure 3:** Smile pre-operative before crown lengthening.



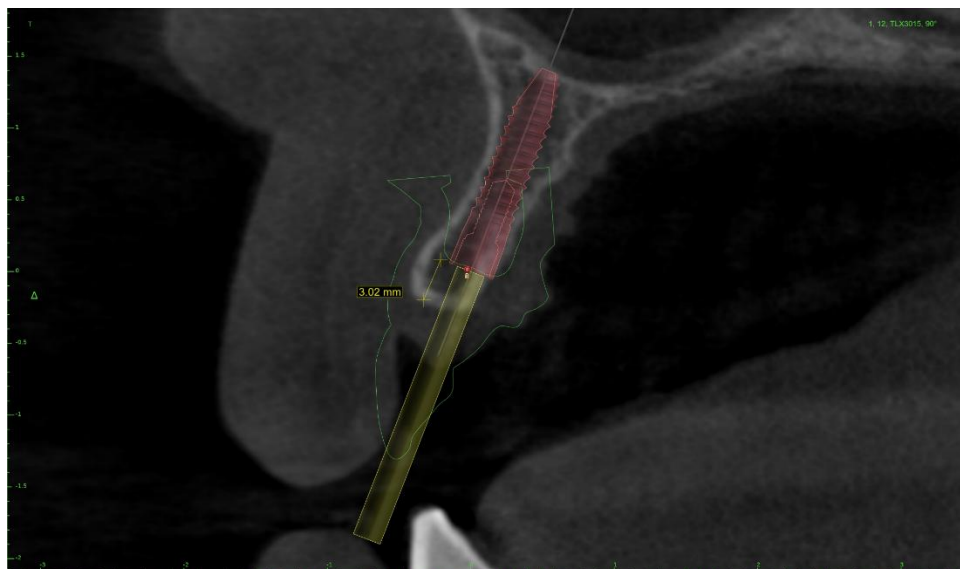
**Figure 4:** Upper arch before crown lengthening.



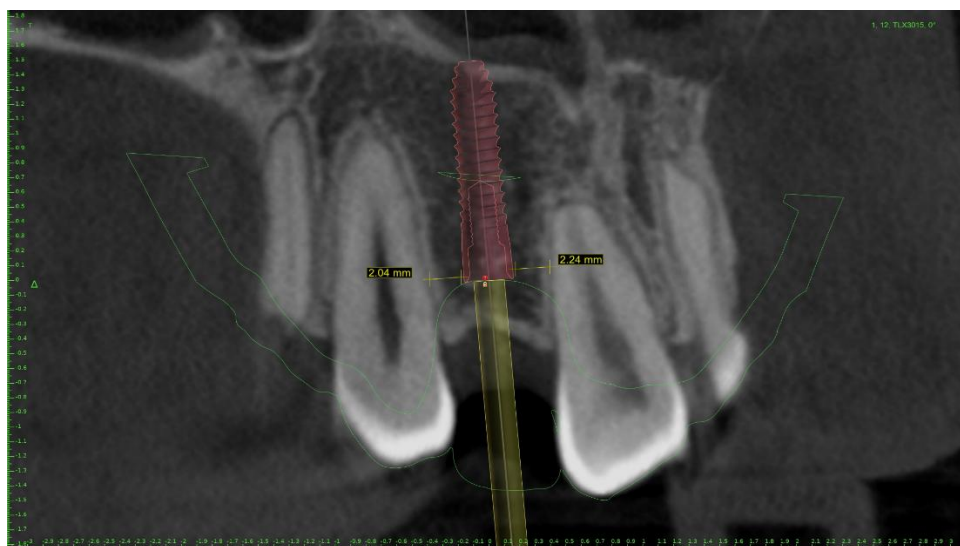**Figure 5:** Upper arch crown lengthening.

### *Phase 3: Digital Prosthetic and Surgical Planning*

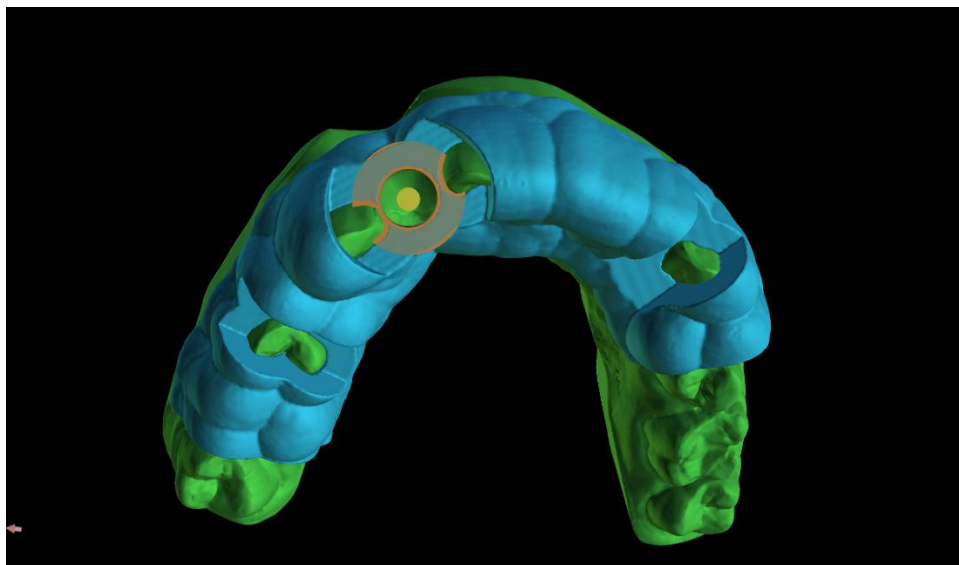
Detailed prosthetic-driven implant planning was carried out for the #12 site. The virtual wax-up developed in Exocad guided the desired crown morphology and the corresponding implant position. CBCT data was imported into BlueSkyPlan4 and the BioHorizons TLX3015 implant was virtually positioned to fulfill prosthetic objectives while maintaining safe interradicular distance from the roots of teeth #11 and #13. A computer-generated surgical guide was fabricated via Guided Solutions using the BioHorizons Complete Guide Kit (Fig. 6-13) [1].



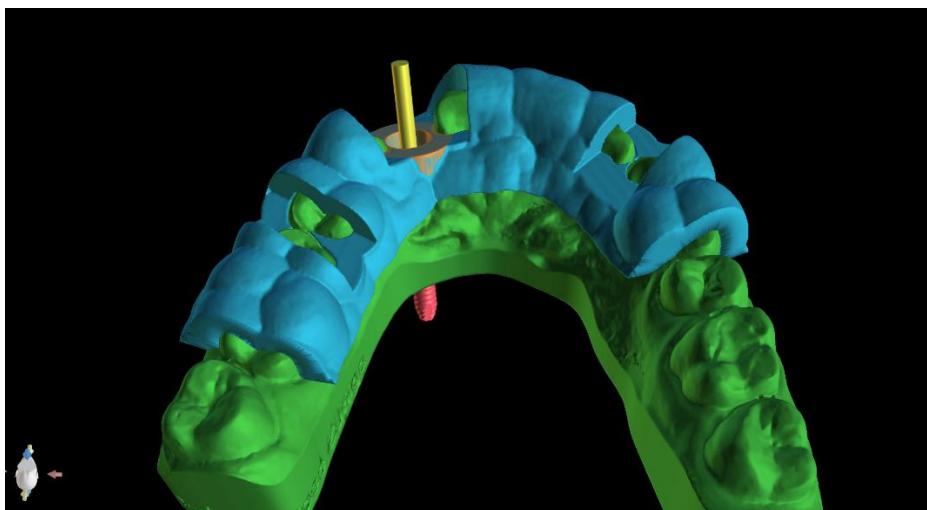
**Figure 6:** Implant Planning, lateral view. CBCT.



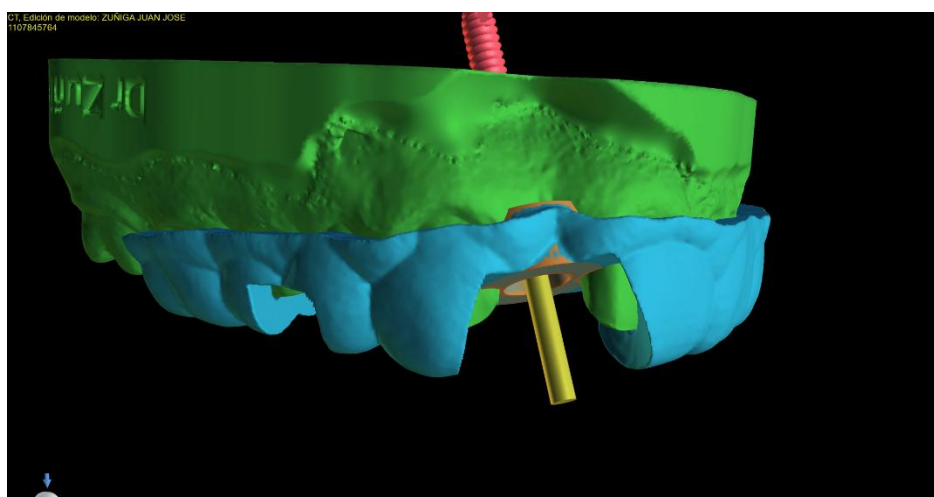
**Figure 7:** Implant planning front view. CBCT



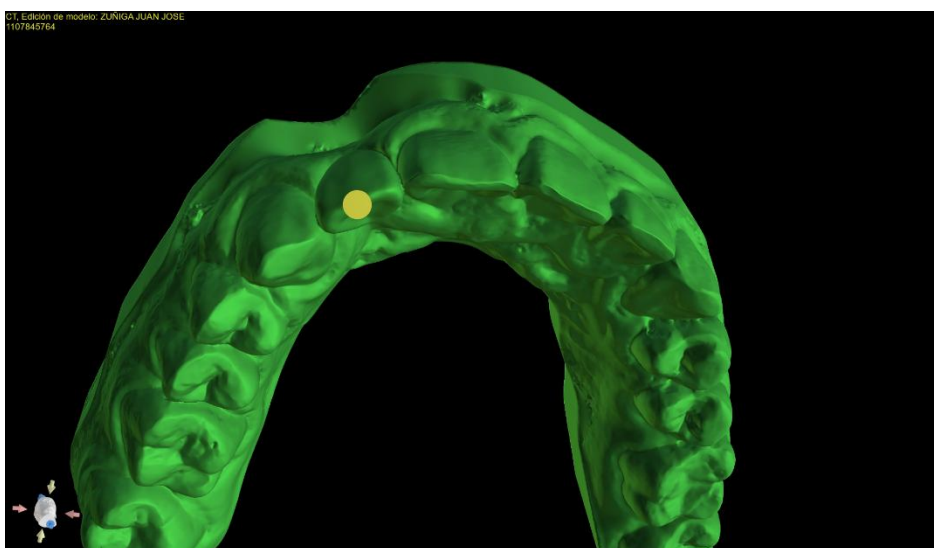
**Figure 8:** Implant guide design.



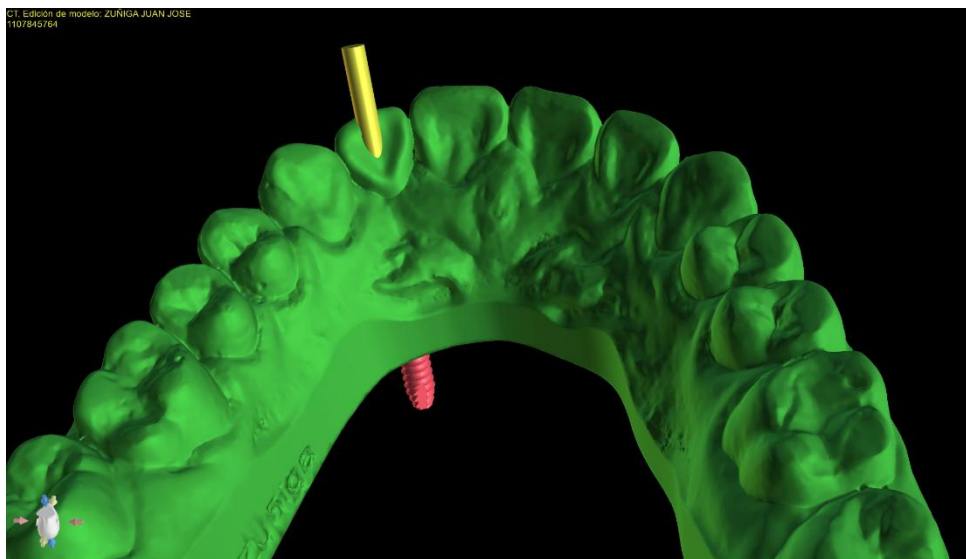
**Figure 9:** Implant guide digital, placement and location. Occlusal view.



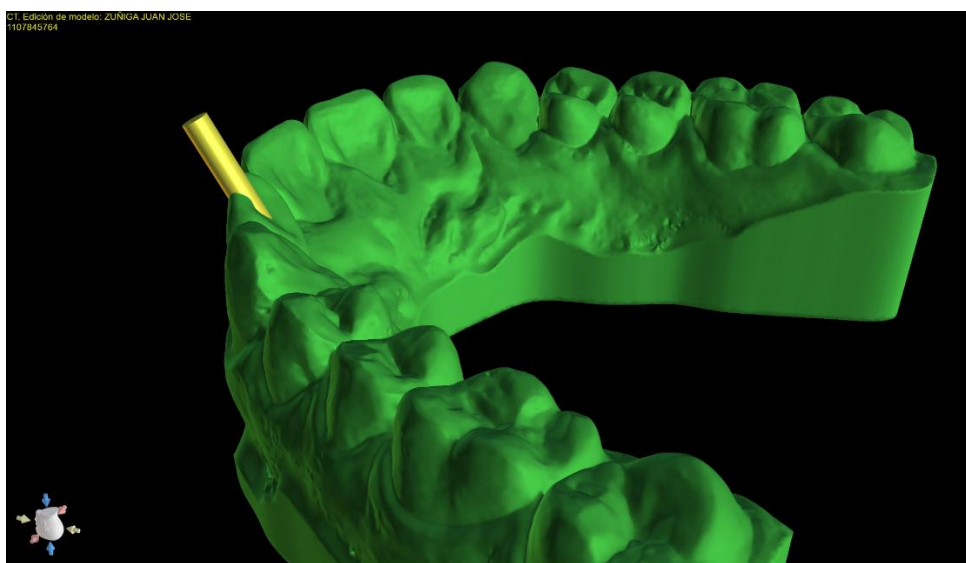
**Figure 10:** Implant guide digital, placement and location. Lateral view



**Figure 11:** Temporary crown design, placement and orientation. Occlusal-lateral view.



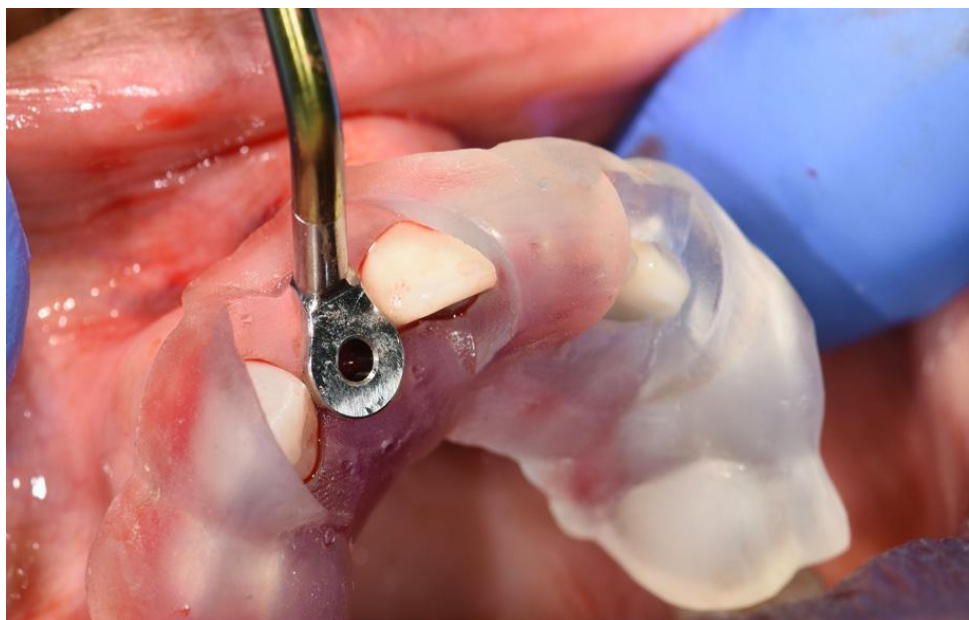**Figure 12:** Temporary Crown Design, placement and orientation. Occlusal view.



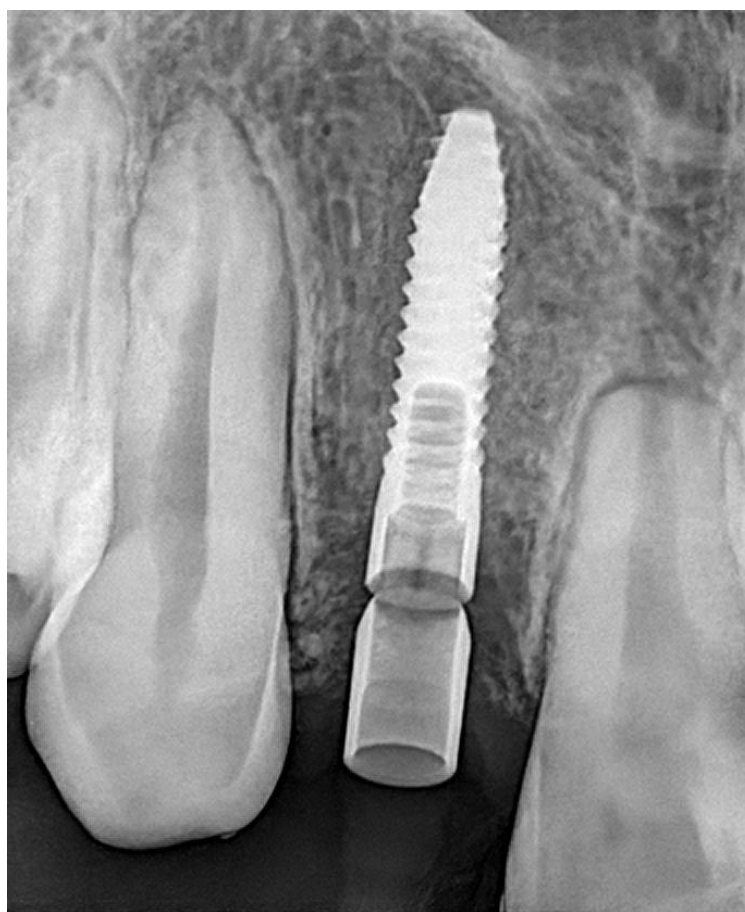
**Figure 13:** Temporary Crown Design, placement and orientation. Lateral view.

#### *Phase 4: Guided Implant Placement and Bone Regeneration*

Implant surgery was performed under local anesthesia using the computer-generated surgical guide. A BioHorizons TLX3015 implant (3 mm × 15 mm) was placed at the planned position with adequate primary stability. Simultaneous Guided Bone Regeneration (GBR) was carried out to address the buccal ridge deformity and augment periodontium thickness. The regenerative protocol included xenograft material (Geistlich Bio-Oss) combined with Platelet-Rich Plasma (PRP). A barrier membrane was positioned to contain the graft and promote organized bone formation. The surgical site was closed with primary intention (Fig. 14,15) [5,6].



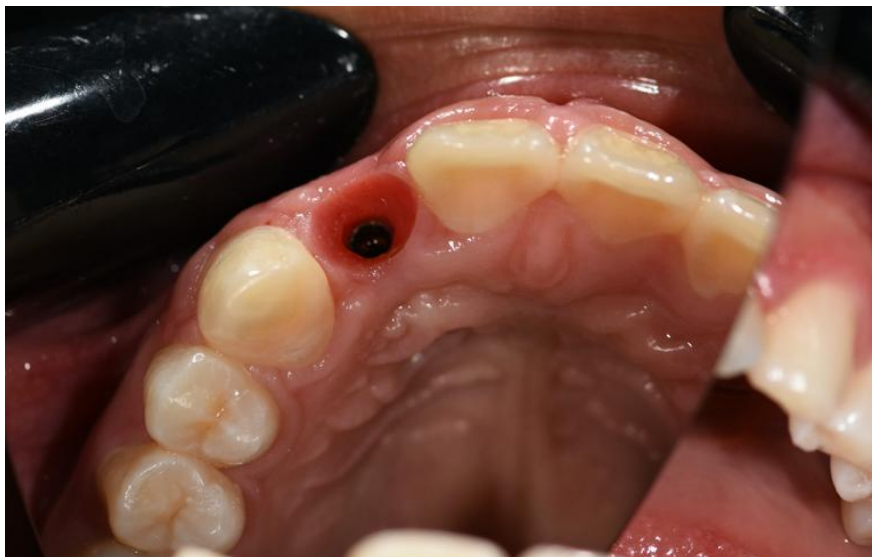**Figure 14:** Implant placement with surgical guide.



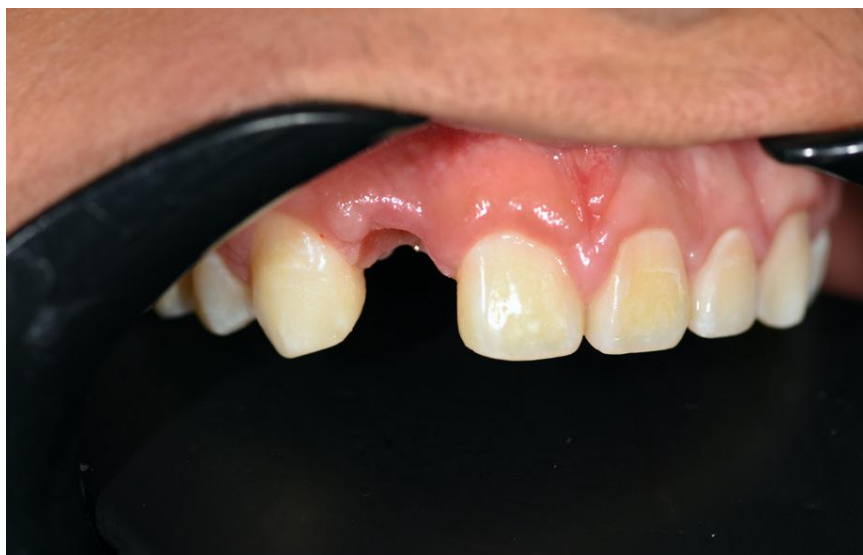**Figure 15:** Periapical X-ray, after implant placement.

*Phase 5: Provisional Restoration and Emergence Profile Development*

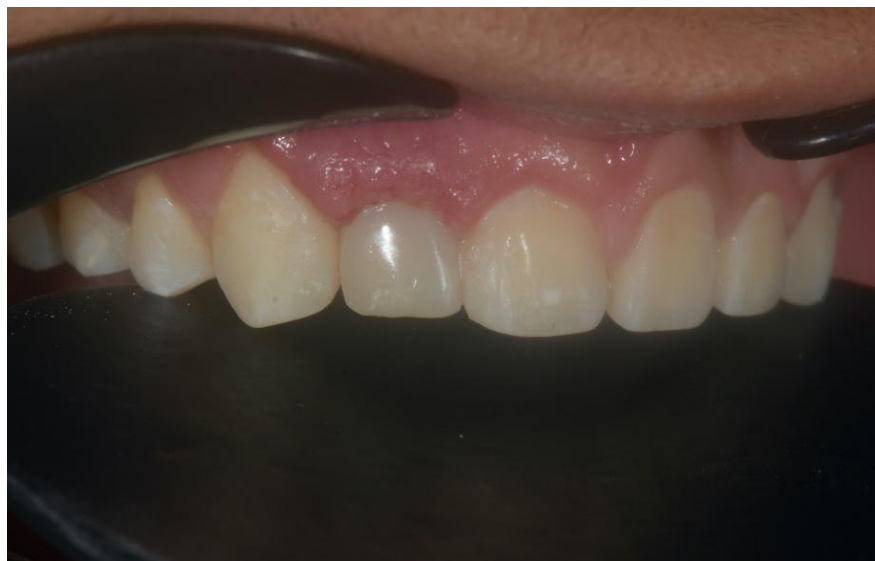Following an osseointegration period, a screw-retained Polymethylmethacrylate (PMMA) temporary crown was fabricated and placed to sculpt the peri-implant soft tissue emergence profile. The provisional was left in function for 3 months, allowing progressive tissue conditioning and profile definition prior to final impression procedures (Fig. 16-18) [5].



**Figure 16:** Emergency profile. Occlusal view.



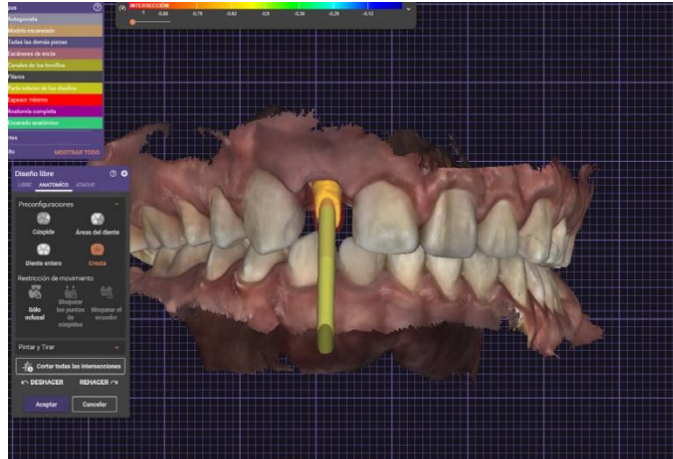
**Figure 17:** Emergency profile. Lateral view.



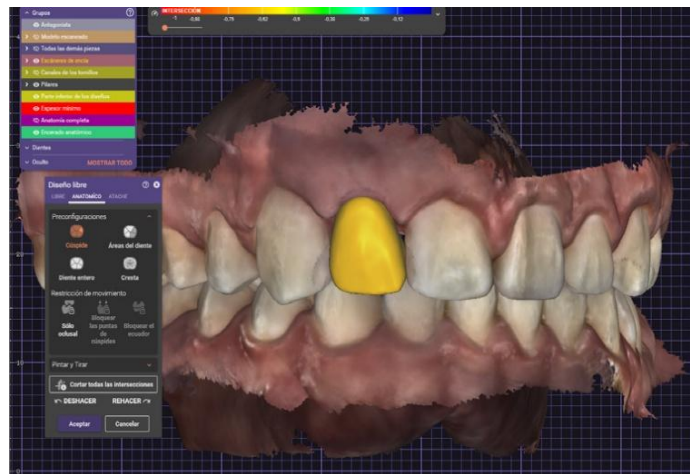
**Figure 18:** Provisional crown placement.

### Phase 6: Definitive Restoration

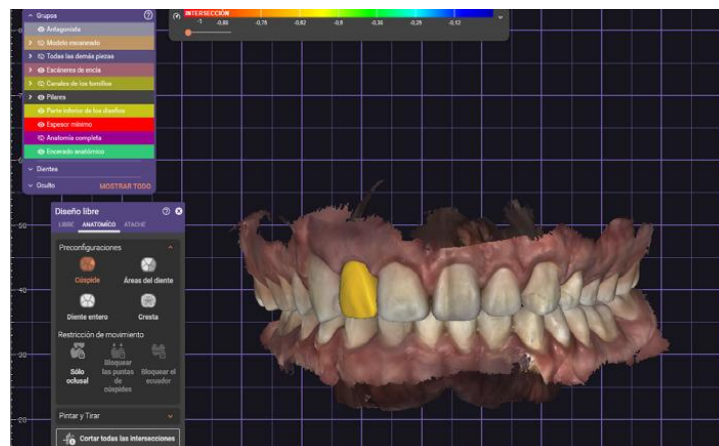
A final intraoral scan captured the matured emergence profile established by the provisional crown. A screw-retained ceramic crown with a Ti-base abutment was fabricated using the digitized emergence profile as a template to ensure soft tissue compatibility. The definitive restoration was delivered and torqued to the manufacturer's recommended specifications. Occlusal contacts were verified in centric and lateral excursions (Fig. 19-28).



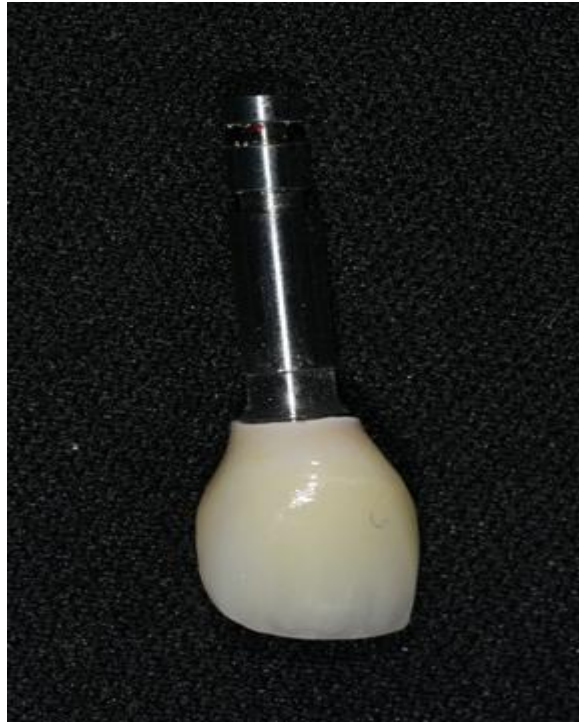**Figure 19:** Design and orientation of the final crown.



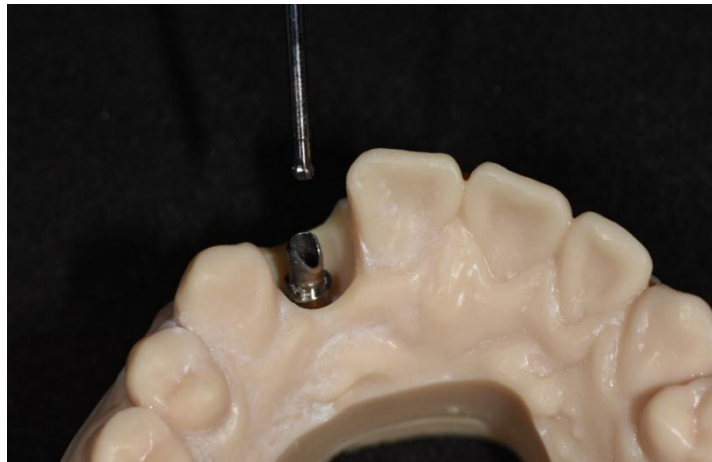
**Figure 20:** Design length and shape of the final crown. Lateral view.



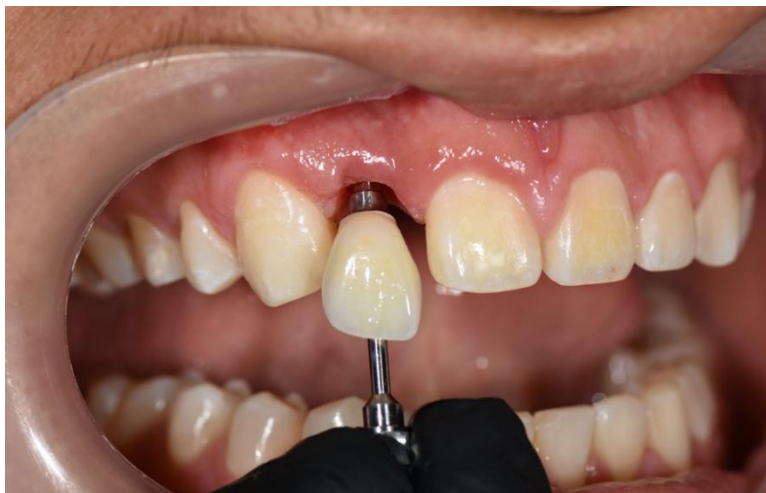**Figure 21:** Design length and shape of the final crown. Front view.



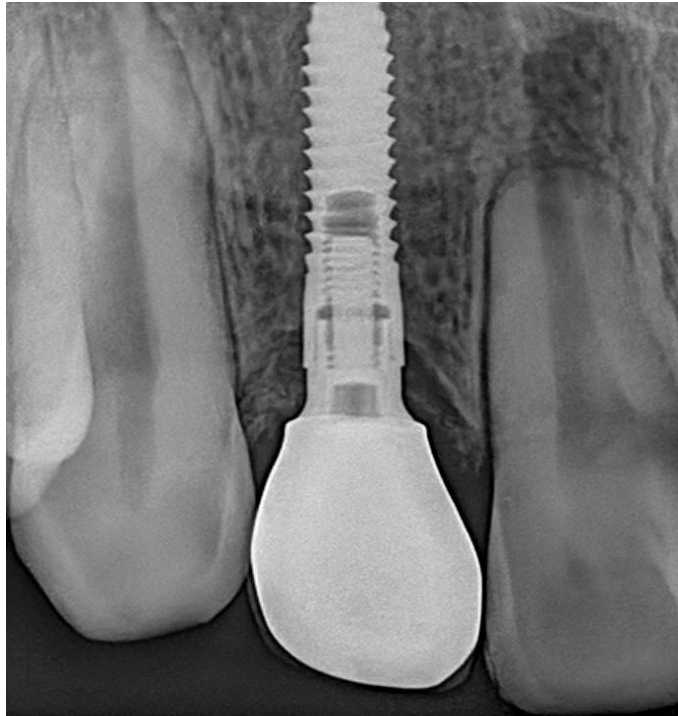
**Figure 22:** Final crown.



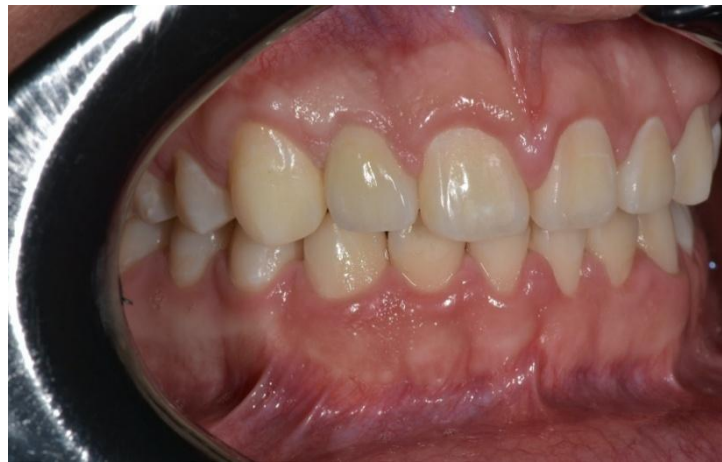**Figure 23:** Custom abutment.



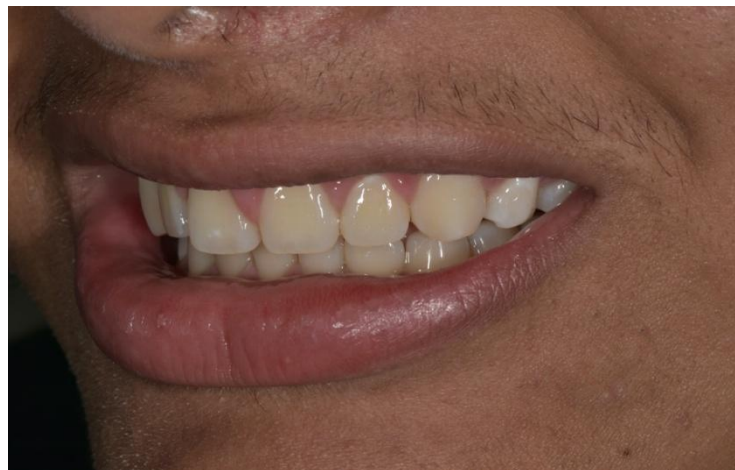**Figure 24:** Final Crown placement, shade and shape matching.



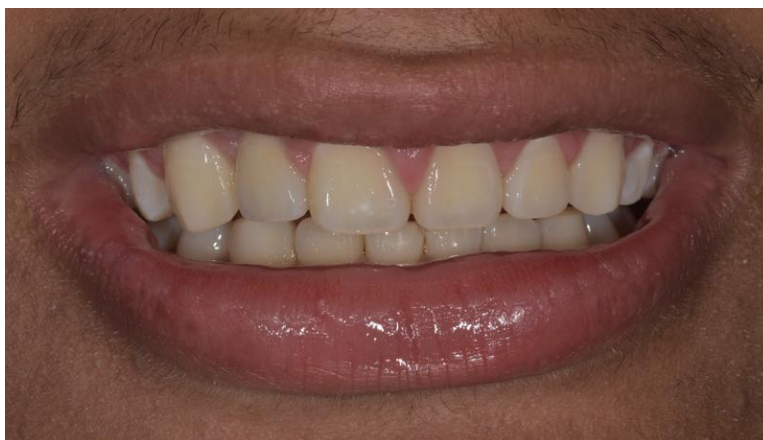**Figure 25:** Final post-operative X-ray after crown placement.



**Figure 26:** Final crown restoration from lateral view.



**Figure 27:** Final crown restoration from lateral view.



**Figure 28:** Final crown restoration.

## Results

The following outcomes were documented at the time of definitive restoration delivery and at subsequent clinical follow-up:

1. Implant osseointegration: Radiographic and clinical examination confirmed stable bone-implant contact with no evidence of peri-implant radiolucency
2. Soft tissue architecture: The 3-month provisional phase established a natural scalloped emergence profile with healthy peri-implant mucosa, appropriate papilla fill and harmonious gingival margins relative to the contralateral and adjacent teeth
3. Esthetic outcome: The definitive ceramic crown demonstrated satisfactory color, shape and surface texture integration with the adjacent dentition, with a favorable smile line contour
4. Functional outcome: Occlusal stability was achieved with verified anterior guidance and canine disocclusion in lateral movements
5. Patient satisfaction: The patient expressed high satisfaction with both the functional and esthetic result, noting significant improvement in smile confidence
6. Complications: No intraoperative or postoperative complications were recorded. Bone regeneration at the GBR site was clinically and radiographically successful

## Discussion

The management of congenitally missing maxillary lateral incisors continues to challenge the interdisciplinary team due to the esthetic sensitivity of the anterior zone, the developmental constraints of young patients and the long-term biological behavior of Osseo-integrated implants in proximity to erupting natural teeth [7].

The decision to pursue orthodontic space opening with subsequent implant rehabilitation, rather than canine substitution, was supported by several clinical factors present in this case [8]. The patient presented with a Class I skeletal relationship, normalized and normally shaped canines that would have been difficult to successfully camouflage as lateral incisors and the absence of significant crowding in the opposing arch. As outlined by Bredariol, et al., these conditions favor space-opening treatment, as canine substitution in such a clinical context would compromise both occlusal function and anterior esthetics [7].

The presence of altered passive eruption (Type I-A) necessitated crown lengthening surgery prior to prosthetic treatment, both to establish correct clinical crown proportions and to define an appropriate restorative margin relationship at the gingival level. Failure to address this soft tissue condition prior to implant-supported rehabilitation would have resulted in disharmonious gingival contours in the final esthetic outcome [9].

The fully digital workflow employed in this case, encompassing intraoral scanning, CAD/CAM wax-up, virtual implant planning and computer-generated surgical guidance, directly enhanced precision of implant placement. The buccal safety margins of 2.04 mm and 2.24 mm from adjacent root surfaces confirmed safe positioning within the narrow interdental space. Computer-guided surgery reduces the risk of root proximity complications, which represents a critical concern in the lateral incisor region due to the limited interradicular space [5,9].

Simultaneous GBR using xenograft and PRP addressed the buccal ridge deformity inherent to the agenesis site. Adequate ridge

volume is a prerequisite for stable peri-implant bone and long-term soft tissue support. The use of PRP as a biological adjunct has been associated with enhanced soft tissue healing and graft incorporation [10].

The 3-month provisional phase was critical to achieving the natural emergence profile and papilla architecture seen at definitive restoration delivery. As supported by contemporary implant prosthodontic principles, the provisional crown serves as a biologic template that conditions the peri-implant tissues before the definitive impression is made, transferring the developed soft tissue morphology to the final restoration [10-12].

A recognized limitation of implant therapy in the esthetic zone is the ankylosed nature of Osseo-integrated implants, which may result in progressive infraocclusion over time as adjacent natural teeth continue to undergo subtle occlusal and positional changes. This concern is amplified in young patients. Long-term follow-up is therefore essential to monitor marginal bone levels, gingival contours and occlusal relationships over time [1,4].

### **Conclusion**

This case demonstrates that the multidisciplinary management of congenitally missing maxillary lateral incisors, when guided by a digitally integrated planning workflow, can achieve predictable and esthetically successful outcomes. Sequential coordination among orthodontic, periodontal, surgical and prosthetic disciplines is essential to address the compound clinical challenges posed by agenesis, including ridge deficiency, altered passive eruption and space limitations and to deliver a restoration that satisfies both functional and esthetic demands. The provisional restoration phase remains a non-negotiable step in esthetic zone implant rehabilitation, as it enables biological tissue conditioning and morphological transfer that cannot be replicated by any other means. Long-term monitoring is recommended to evaluate peri-implant tissue stability and occlusal integrity as the patient transitions through adulthood.

### **Conflict of Interest**

The authors declared no potential conflicts of interest with respect to the research, authorship and/or publication of this article.

### **Funding Statement**

This research did not receive any specific grant from funding agencies in the public, commercial or non-profit sectors.

### **Acknowledgement**

The authors have no acknowledgments to declare.

### **Data Availability Statement**

The data supporting the findings of this study are available from the corresponding author upon reasonable request.

### **Ethical Statement**

The project did not meet the definition of human subject research under the purview of the IRB according to federal regulations and therefore was exempt.

### **Informed Consent Statement**

Informed consent was obtained from all participants included in the study.

### **Authors' Contributions**

All authors contributed equally to this paper.

### **References**

1. Bredariol A, Pasinato F, Bredariol C, Cardoso M. Orthodontic treatment choice in case of unilateral and bilateral upper lateral incisors agenesis: An overall flowchart. *Int J Clin Dent*. 2021;14(1):27-40.
2. Schneider U, Moser L, Wismeijer D, Jung RE. Esthetic evaluation of implants versus canine substitution in patients with congenitally missing maxillary lateral incisors. *Am J Orthod Dentofacial Orthop*. 2016;150(3):416-24.
3. Kiran Kumar K, Kumar NS, Sowmya N, Tanveer K, Shameem K, Kumar S. Pre-prosthetic orthodontic implant site <https://doi.org/10.46889/JDHOR.2026.7206> <https://athenaeumpub.com/journal-of-dental-health-and-oral-research/>

- preparation for management of congenitally unerupted lateral incisors: A case report. *J Int Dent Med Res*. 2013;6(1):40-4.
4. Sharma PK, Sharma P. Interdisciplinary management of congenitally absent maxillary lateral incisors: Orthodontic/prosthetic perspectives. *Semin Orthod*. 2015;21(1):27-37.
  5. Esposito M, Grusovin MG, Maghaireh H, Coulthard P, Worthington HV. Interventions for replacing missing teeth: Different times for loading dental implants. *Cochrane Database Syst Rev*. 2013;(3):CD003878.
  6. Wallace SS, Froum SJ. Effect of maxillary sinus augmentation on the survival of endosseous dental implants: A systematic review. *Ann Periodontol*. 2003;8(1):328-43.
  7. Negi A, Amita. Interdisciplinary management of congenitally missing maxillary lateral incisors. *J Oral Biol Craniofac Res*. 2020;10(2):184-8.
  8. Althubaiti MM, Alharbi AS, Aljuaid FA, Alotaibi RA, Alghamdi KS. Esthetic, periodontal and functional outcomes of orthodontic space closure versus prosthetic replacement for congenitally missing maxillary lateral incisors: A systematic review. *Cureus*. 2026;18(1):e101260.
  9. Enfedaque-Prat M, González-Barnadas A, Jorba-García A, Vilarrasa J, Toledano-Serrabona J, Figueiredo R, et al. Accuracy of guided dual technique in esthetic crown lengthening: a prospective case-series study. *J Esthet Restor Dent*. 2025;37(6):1284-96.
  10. Shanaman R, Filstein MR, Danesh-Meyer MJ. Localized ridge augmentation using GBR and platelet-rich plasma: Case reports. *Int J Periodontics Restorative Dent*. 2001;21(4):345-55.
  11. Prasher P, Tuteja A, Amin F, Sopaj R, Tuteja D, Sharaf Eddin H. Advancing precision: The role of digital workflows in modern implant dentistry. *Bioinformation*. 2025;21(8):2490-5.
  12. Tu KW, Kuo CH, Hung CC, Yan DY, Mau JLP. Strategic sequencing of orthodontic treatment and periodontal regenerative surgery: A literature review. *J Dent Sci*. 2025;20(3):1391-7.

## About the journal



Journal of Dental Health and Oral Research is an international, peer-reviewed, open-access journal published by Athenaeum Scientific Publishers. The journal publishes original research articles, case reports, editorials, reviews and commentaries relevant to its scope. It aims to disseminate high-quality scholarly work that contributes to research, clinical practice and academic knowledge in the field.

All submissions are evaluated through a structured peer-review process in accordance with established editorial and ethical standards. Manuscripts are submitted and processed through the journal's online submission system.

**Manuscript submission:** <https://athenaeumpub.com/submit-manuscript/>